

# Western Trauma Association Critical Decisions in Trauma: Management of adult blunt splenic trauma—2016 updates

Susan E. Rowell, MD, Walter L. Biffl, MD, Karen Brasel, MD, Ernest E. Moore, MD, Roxie A. Albrecht, MD, Marc DeMoya, MD, Nicholas Namias, MD, Martin A. Schreiber, MD, Mitchell J. Cohen, MD, David V. Shatz, MD, Riyadh Karmy-Jones, MD, and Frederick A. Moore, MD, Portland, Oregon

This is an updated position article from members of the Western Trauma Association (WTA). It includes recommendations for the management of blunt splenic injury in adult trauma patients based on literature available since the last WTA position article in 2008.<sup>1</sup> There remain no prospective randomized trials of the management of blunt splenic injury in adults, in part due to the inherent difficulties of designing such a trial. This algorithm and associated recommendations are based primarily on observational studies and expert opinion. Considerable variability in the management of blunt splenic injury will continue. Individual institutions and practitioners are encouraged to make management decisions based on local resources and consensus opinion. The algorithm contains letters A through I, which correspond to the lettered text in the manuscript. As in the previous position article, the text is designed to clarify the algorithm and explain the rationale for the recommendations.

## HISTORICAL PERSPECTIVE

The management of blunt splenic injury has evolved significantly over the years. Initially, surgeons were hesitant to apply nonoperative management (NOM) to splenic injuries due to a perceived high failure rate;<sup>1-3</sup> however, later reports on pediatric patients demonstrated that NOM could have a high success rate.<sup>4-6</sup> As a result, by the 1990s, NOM had become the standard of care for hemodynamically stable adults.<sup>7</sup> Over the past 20 years, success rates for NOM have continued to improve, with rates greater than 90% in most centers.<sup>8</sup> Unfortunately, there remains no standard definition of failure of NOM, and a wide variability in published failure rates exists for all grades of splenic injury. It remains uncertain whether the decrease in reported failure rates of NOM is due to better patient selection,

increasing use of splenic artery angioembolization (SAE), or changing definitions of failure of NOM. Since the last position statement by the WTA was published, data increasingly question the significance of factors previously thought to predict failure of NOM including transfusion requirements, advanced age, and brain injury.<sup>1</sup> Significant variability among centers regarding the definition of hemodynamic instability, resuscitation strategies, and availability and indications for angiography continue to make results difficult to interpret. Other issues that remain unclear include the optimal indications and timing for repeat imaging, as well as the timing of venous thromboembolism prophylaxis and postsplenectomy vaccinations. Results from a prospective multicenter observational trial supported by the American Association for the Surgery of Trauma examining factors associated with failure of NOM for blunt splenic injury were recently published and addressed some of these issues;<sup>9</sup> however, at the present time, management is primarily based on observational data, expert opinion, and local resources. This algorithm is based on the available data, the interpretation of these data by our membership, and the collective experience of the WTA and is meant to serve as a guide for decision making regarding management of blunt splenic injury.

## Initial Evaluation

The initial evaluation of a patient with blunt abdominal trauma should follow basic principles as outlined by Advanced Trauma Life Support. These will not be repeated here. Many definitions of hemodynamic instability exist, but to date, none have been conclusively validated. Instability is typically determined by initial vital signs. The response to volume infusion and need for ongoing resuscitation should also be considered in the assessment of hemodynamic instability.

Submitted: March 11, 2016, Revised: October 6, 2016, Accepted: October 20, 2016, Published online: November 23, 2016.

From the Oregon Health & Science University, Portland, Oregon (S.E.R., M.A.S., K.B.); The Queen's Medical Center, University of Hawaii, Honolulu, Hawaii (W.B.); College of Medicine, University of Oklahoma, Oklahoma City, Oklahoma (R.A.A.); University of California, San Francisco, San Francisco, California (M.J.C.); Massachusetts General Hospital, Boston, Massachusetts (M.D.); Legacy Emanuel Hospital, Portland, Oregon (R.K.-J.); Denver Health Medical Center, Denver, Colorado (E.E.M.); University of Miami, Miami, Florida (N.N.); University of California, Davis, Sacramento, California (D.V.S.); and University of Florida College of Medicine, Gainesville, Florida (F.A.M.).

Presented at the 45th annual meeting of the Western Trauma Association, March 1-6, 2015, in Telluride, Colorado.

This algorithm has not been published elsewhere.

Disclaimer: The Western Trauma Association (WTA) develops algorithms to provide guidance and recommendations for particular practice areas but does not establish the standard of care. The WTA algorithms are based on the evidence available in the literature and the expert opinion of the task force in the recent timeframe of the publication. The WTA considers use of the algorithm to be voluntary. The ultimate determination regarding its application is to be made by the treating physician and health care professionals with full consideration of the individual patient's clinical status as well as available institutional resources; it is not intended to take the place of health care providers' judgment in diagnosing and treating particular patients.

Address for reprints: Susan E. Rowell, MD, MCR, 3181 SW Sam Jackson Park Rd, L611, Portland, OR 97239; email: rowells@ohsu.edu.

DOI: 10.1097/TA.0000000000001323

*J Trauma Acute Care Surg*  
Volume 82, Number 4

## Positive Focused Assessment with Sonography in Trauma

Hemodynamically unstable patients should have a focused assessment with sonography in trauma (FAST) examination performed early during the initial resuscitation. Patients with a positive FAST result that stabilize after a brief period of resuscitation can potentially proceed to have a computed tomographic (CT) scan performed if it can be obtained rapidly and surgical resources are readily available. Patients with a positive FAST examination that stabilize after a brief period of resuscitation can potentially proceed to have a computed tomographic (CT) scan performed if it can be obtained rapidly and surgical resources are readily available. Patients with a positive FAST examination with persistent or severe hemodynamic instability should proceed directly to the operating room.

## Negative FAST

A negative FAST examination result in a hemodynamically unstable patient does not rule out intraperitoneal hemorrhage. If the instability persists after a brief period of resuscitation, a repeat FAST examination should be performed and a diagnostic peritoneal aspirate should be strongly considered to confirm the negative FAST examination result. If there is no evidence of intra-abdominal hemorrhage based on a negative FAST examination as well as a negative confirmatory test, other sites of hemorrhage (chest, pelvis, extremities, wounds) and other causes of shock (i.e., cardiogenic, neurogenic) should be considered. If no alternative etiology of shock is identified and the patient continues to exhibit profound hemodynamic instability, emergent laparotomy should be strongly considered. Contrast-enhanced ultrasound has been used in Europe and in a few US centers to diagnose solid organ injuries. Small pilot studies have shown that the sensitivity of this modality is still less than CT scan; and in the United States, it has not entered mainstream practice.<sup>10</sup>

## Operative Management

Hemodynamically unstable patients who do not respond to initial resuscitation should generally undergo laparotomy. If a splenic injury is identified, splenectomy is usually performed unless the injury is minor and is not the primary source of blood loss. Splenic salvage techniques may be attempted in select hemodynamically stable patients with anatomically appropriate injuries. A variety of techniques have been described including application of topical agents, cautery, argon beam coagulation, pledgeted suture repair, mesh wrapping, and partial splenectomy. In an effort to preserve splenic tissue, splenic autotransplantation has been performed. While data are conflicting, an improved immunoglobulin response to pneumococcal vaccination following autotransplantation has been reported.<sup>11,12</sup> In practice, splenic salvage techniques are rarely used, as the intraoperative threshold for splenectomy tends to be low, even for lower-grade injuries.<sup>13</sup> This trend may continue to be an issue given the limited experience of recent surgical trainees to splenic procedures for trauma.<sup>14</sup>

## Computed Tomography

Hemodynamically stable patients should undergo CT if no other indication for urgent intervention is present. An abdominal CT scan with intravenous contrast is the criterion standard for determining the grade of splenic injury and the presence of

contrast extravasation from the vascular system. The venous phase of a two-phase CT scan can best distinguish contrast extravasation from small arteries by demonstrating contrast pooling at the site of injury. Extravasated contrast may indicate active intraperitoneal hemorrhage or a contained vascular lesion and is frequently considered to be an indication for angiography.<sup>7,15</sup>

## Nonoperative Management—Overview

With better patient selection and increasing use of angioembolization, the reported failure rates for NOM have dropped significantly in some centers, even for high-grade injuries.<sup>8</sup> Despite this, significant variability in reported failure rates for NOM remains. A recent meta-analysis estimated the failure rate for observation alone to be as high as 43.7% for Grade IV injuries and 83.1% for Grade V injuries.<sup>8</sup> Many studies have sought to determine clinical factors that predict failure of NOM; however, most of the existing data are based primarily on retrospective and single-center studies. In these series, as many as 14 different factors have been shown to be significant predictors of failure of NOM.<sup>16</sup> A recent systematic review of the literature concluded that failure of NOM is higher in patients with Grade III and higher-grade injuries, in patients older than 40 years, and in those with an Injury Severity Score (ISS) of 25 or higher.<sup>16</sup> Advanced age was previously thought to predict failure of NOM, but this has recently been called into question.<sup>17</sup> Despite the large body of literature on the subject, no single factor has consistently been shown to predict failure of NOM sufficiently enough to recommend mandatory operation in an otherwise hemodynamically stable patient. The presence of hemoperitoneum may make it more difficult to identify a hollow viscus injury; however, the incidence of hollow viscus injuries in patients initially selected for NOM of splenic injury is relatively low.<sup>18</sup> Concern for other missed abdominal injuries should generally not influence the initial decision to proceed with NOM. In cases in which NOM of a splenic injury is attempted, there should be ready availability of an operating room and surgical staff. The facility should have the capability to administer blood products. For higher-grade injuries, monitored beds should be available. Patients who have splenic injuries identified in facilities without these capabilities should be transferred to an appropriate center.

## Grade I and Grade II Injuries (Table 1)

The failure rate of NOM for Grade I and Grade II spleen injuries is low. Nonoperative management should be pursued unless another indication for laparotomy is present.<sup>1,7,19</sup> Splenic artery angioembolization is generally not performed for Grade I or Grade II injuries unless foci of contrast extravasation are present; and even then, the practice is controversial since spontaneous thrombosis often occurs.<sup>20,21</sup> In these patients, consideration for a repeat imaging (rather than SAE) to demonstrate resolution of the blush should be given since failure rates as high as 70% have been reported for observation of stable patients with low-grade injuries and a blush.<sup>22</sup>

## Grade III Injury (Table 1)

Most Grade III injuries are amenable to NOM with success rates ranging from 70% to 90% in most recent series (Table 2).<sup>21,24–28</sup> Whether or not to perform angiography in

**TABLE 1.** American Association for the Surgery of Trauma Splenic Injury Scale (1994 revision)<sup>66</sup>

Grade	Injury Description
I	Hematoma subcapsular, <10% surface area Laceration capsular, <1cm parenchymal depth
II	Hematoma subcapsular, 10–50% surface area, <5-cm diameter Laceration 1- to 3-cm depth, which does not involve trabecular vessel
III	Hematoma subcapsular, >50% surface area or expanding. Ruptured subcapsular or parenchymal hematoma Intraparenchymal hematoma >5 cm or expanding Laceration > 3-cm depth or involving trabecular vessels
IV	Laceration involving segmental or hilar vessels producing major devascularization (>25% of spleen)
V	Laceration, completely shattered spleen Vascular, hilar vascular injury, which devascularizes spleen

patients with Grade III splenic injuries remains one of the most controversial areas surrounding of the management of blunt splenic injury. One study recommended angiography for all Grade III injuries and higher based on an improved success rate of NOM compared to historical controls.<sup>25</sup> While some authors continue to recommend angiography for all Grade III injuries, this is practiced only in a small number of institutions.<sup>25</sup> At the present time, whether or not to perform angiography in patients with Grade III splenic injuries remains controversial. In patients with Grade III injuries that are noted to have an associated contrast blush, stronger consideration for performing angiography should be considered.<sup>23</sup> Based on the currently available data and widely varying practice patterns, both observation and angiography remain acceptable options. In patients with a contrast blush, the need for a repeat imaging to demonstrate resolution also remains unclear but consideration is recommended.

### Grade IV and Grade V Injuries (Table 1)

Historically, most patients with Grade IV and Grade V injuries have undergone operative management even when hemodynamically stable. In recent years, however, NOM of Grade IV and Grade V splenic injuries in selected patients has been increasingly performed. For these high-grade injuries, angiography has been increasingly advocated as an important adjunct to NOM,<sup>25,29</sup> as it seems to improve the success rate in some centers.<sup>21,30,31</sup> Although it is presumed that the success of NOM is related to the use of angiography with/without embolization resulting in decreased splenic bleeding, this has not been clearly demonstrated. Results remain difficult to interpret as existing studies have been subject to confounders (including differing indications for angiography and embolization, different definitions of failure, and a difference in the proportion of patients with a contrast blush), making it difficult to compare failure rates. Furthermore, studies that use historical controls to demonstrate improved success of NOM in patients undergoing angiography and SAE are likely subject to bias.<sup>32</sup> Regardless, the existing data are compelling as patients with Grade IV/V injuries who do not undergo angiography have continued to demonstrate high failure rates for NOM, generally greater than

40%.<sup>8,22,24,29</sup> In one multicenter retrospective study including 388 patients from 14 trauma centers in New England with Grade IV and Grade V injuries in which angiography was rarely used, the overall observed failure rate was 64%. Of note, 42% of the cohort underwent immediate operation with no attempt at NOM. Of the remaining 58% of patients who were managed nonoperatively, 35% of patients with Grade IV injuries and 60% of patients with Grade V injuries went on to fail. Thus, the total number of patients who underwent an operation for splenic injury was 60% for Grade IV injuries and 84% for Grade V injuries. It is important to note that while fewer patients with Grade IV injuries failed, this group accounted for 80% of the failures due to the higher number of patients with Grade IV injuries.<sup>22</sup> In centers performing mandatory angiography for all patients with Grade IV and Grade V splenic injuries undergoing NOM, failure rates of less than 10% (Table 2) have been reported leading to an increasing number of centers performing angiography and SAE for all patients with Grade IV and Grade V injuries.<sup>24,25</sup> Based on these emerging data, it is recommended that SAE be strongly considered in patients with Grade IV and Grade V injuries with or without a contrast blush as a significant percentage of patients with high-grade injuries who do not undergo SAE at the time of angiography have been shown to rebleed and require later intervention (usually splenectomy),<sup>25,33,34</sup> with failure rates as high as 26% reported.<sup>26</sup> It is important to note, however, that patients who are persistently hypotensive after initial resuscitation should undergo splenectomy and should not undergo angiography. Furthermore, even in patients in whom SAE is performed, the failure rate remains high,<sup>23</sup> particularly in the presence of hypotension or large hemoperitoneum.<sup>35</sup> Accordingly, in patients who develop hypotension after SAE, splenectomy should be strongly considered.

**TABLE 2.** Outcome of NOM in Patients with High-Grade Spleen Injuries in Clinical Series with More Than 100 Patients Since 2008

Study	#	#NOM (%)	Failure of NOM (%)	#SAE (%)
<b>Grade III</b>				
University of Mississippi 2008 <sup>23</sup>	46*	25 (54)	6 (24)	All
Oslo University 2013 <sup>24</sup>	116	87 (75)	4 (5)	50 (57)
Wake Forest 2014 <sup>25</sup>	168	134 (80)	10 (7.5)	65 (49)
Case Western 2009 <sup>21</sup>	159	146 (92)	9 (6)	60 (41)
University of Florida 2012 <sup>26</sup>	n/a	87**	5 (6)	24 (28)
Montpellier 2012 <sup>27</sup>	50	37 (74)	6 (26)	4 (11)
UCSF Fresno 2008 <sup>28</sup>	209	144 (69)	8 (6)	11 (8)
<b>Grade IV-V</b>				
University Mississippi 2008 <sup>23</sup>	70*	25 (36)	16 (64)	All
Oslo Univ. 2013 <sup>24</sup>	91	64 (70)	3 (5)	All
Wake Forest 2014 <sup>25</sup>	74	35 (74)	3 (8)	All
Case Western 2009 <sup>21</sup>	165	121 (73)	18 (25)	80 (66)
University Florida 2012 <sup>26</sup>	n/a	94**	14 (15)	61 (65)
Montpellier 2012 <sup>27</sup>	53	37 (59)	8 (22)	8 (15)
UCSF Fresno 2008 <sup>28</sup>	109	46 (42)	6 (13)	6 (6)
Multicenter 2010 <sup>22</sup>	388	224 (58)	85 (38)	“handful”

\*Only patients with a contrast blush were included in this study.

\*\*This study included only patients undergoing nonoperative management (NOM).

## OTHER CONSIDERATIONS

### Proximal Versus Distal SAE

In patients who do undergo SAE, whether to perform proximal or distal SAE has not been determined. If no contrast blush is identified, proximal splenic artery embolization is often performed. Proximal embolization decreases overall blood flow to the splenic parenchyma without causing overt infarction.<sup>36</sup> Distal embolization may have a higher rate of focal splenic infarction but has been thought to be more appropriate when specific foci of extravasation are identified. The clinical significance of the observed focal splenic infarction remains questionable, in part owing to low statistical power in the studies that have examined this issue.<sup>36</sup> Patients with focal infarction of the splenic parenchyma may be symptomatic but can usually be managed with standard analgesics alone.<sup>34</sup> Neither proximal nor distal splenic artery embolization has been definitively shown to be superior to the other in rebleeding or complication rates; however, they have not been compared in a randomized fashion.<sup>36</sup> In general, the immunologic function of the spleen is thought to be preserved after proximal or distal SAE,<sup>18,37</sup> although there is no definitive evidence, as a reliable marker for splenic immune function has not been identified.<sup>12</sup> Additional complications after SAE include splenic abscess formation, infarction, visceral vessel injury, complications related to vascular access, and contrast nephropathy.<sup>34,38</sup> The decision to perform proximal or distal embolization should be based on discussion with the treating interventional radiologist and is beyond the scope of this algorithm.

In patients who undergo SAE, a second CT scanning at 48 to 72 hours should be considered to rule out persistent or new pseudoaneurysm development. The management of a persistent pseudoaneurysm or new pseudoaneurysm in an alternate location after SAE is beyond the scope of this algorithm; however, based on anecdotal experience, a percentage of these patients will go on to develop rupture of a pseudoaneurysm. Thus, consideration for additional imaging and intervention should be considered. A second CT scanning at 48 to 72 hours should be considered even in those who do not undergo SAE at the time of initial angiography to rule out the development of a new pseudoaneurysm. All patients with Grade IV and Grade V injuries selected for NOM should be admitted to an intensive care unit and placed on bedrest until stable and for at least 24 hours. While the optimal duration and frequency of serial hemoglobin measurements also remain unclear in high-grade injuries, hemoglobin measurements should be obtained 2 hours after arrival and every 6 hours for 48 hours and continued until at least two stable measurements are obtained. Consideration should be given to additional monitoring for patients with a contrast blush or subcapsular hematoma.<sup>39</sup>

### Impact of Splenectomy on Immune Function and Other Organ Systems

Overwhelming postsplenectomy infection is a potentially lethal complication that can occur in the asplenic state. It is rare in adults, with an estimated incidence of 0.05%, or approximately 0.07 cases per 100 person-years of exposure.<sup>40</sup> Many trauma surgeons consider the risk of overwhelming postsplenectomy infection to be overemphasized.<sup>1</sup> Splenectomy has other adverse

effects on the immune system and less is known about the impact of splenectomy on early infectious complications after injury. One recent prospective multicenter study demonstrated that splenectomy was an independent risk factor for postinjury infectious complications as a whole demonstrating an increase in the rate of intra-abdominal abscesses, wound infections, pneumonia, and septicemia.<sup>13</sup> Splenectomy after trauma has also been associated with the subsequent development of type II diabetes,<sup>41,42</sup> although this has been questioned.<sup>43</sup> Splenectomy has also been associated with a persistent hypercoagulable state,<sup>44</sup> increased incidence of venous thromboembolism,<sup>45</sup> and increased incidence of subsequent cancers.<sup>46</sup> In addition, NOM has been associated with lower hospital length of stay and overall cost.<sup>47</sup>

### Recommendations for Postsplenectomy Vaccinations

Patients that have undergone a splenectomy should receive the pneumococcal vaccine Prevnar 13 followed by Pneumovax 23 at least 8 weeks after the initial vaccination. *Haemophilus influenzae* type B and meningococcal vaccines should be administered along with the initial pneumococcal vaccine.<sup>48</sup> While the optimal timing for postsplenectomy immunizations remains unclear,<sup>49,50</sup> based on available human data, administration of vaccines should be performed on postoperative Day 14. In practice, however, many centers administer vaccines before hospital discharge owing to concerns with patient follow-up and the difficulty with obtaining the vaccines as an outpatient. Detailed guidelines on revaccination based on age and underlying risk factors can be found on the CDC website.<sup>51</sup>

### Delayed Splenic Rupture

The true incidence of delayed splenic rupture (DSR) remains unknown.<sup>1,7</sup> Delayed splenic rupture has been traditionally managed operatively, almost always by splenectomy.<sup>14</sup> Successful splenorrhaphy after DSR is very rare. There have been some reports of management of DSR by angiography and SAE or even with observation alone.<sup>52,53</sup> In general, NOM of DSR has been described only in a few small case series, and its routine use cannot be recommended. It may be considered for certain carefully selected patients in a highly monitored setting.

### Chemical Deep Venous Thrombosis Prophylaxis

Current practices regarding the timing of initiation of chemical deep venous thrombosis (DVT) pharmacoprophylaxis for both low- and high-grade injuries vary widely among trauma centers.<sup>39</sup> While the decision to initiate DVT pharmacoprophylaxis in patients undergoing NOM for a splenic injury should be individualized, available human data using thromboelastography suggest that patients with blunt solid organ injury transition from a hypocoagulable to a hypercoagulable state between 36 and 48 hours after injury. Two studies have suggested that chemical DVT pharmacoprophylaxis is safe starting within 48 to 72 hours in patients undergoing NOM, but these studies included low numbers of patients with Grade III to Grade V injuries.<sup>54,55</sup> At present, initiation of DVT pharmacoprophylaxis should be based on the patient's hemodynamic and bleeding status, but consideration should be given for initiation within 48 hours after injury if no contraindications exist. The decision making

**TABLE 3.** Monitoring and Treatment Considerations Based on Splenic Injury Grade

Injury Grade	ICU Admission	Hemoglobin Frequency and Duration	Bedrest	Return to Activity
I	Not required*	q 8 hours × 24 hours*	None	4 weeks
II-III	At least 24 hours*	q 6 hours × 24 hours and every 12 hours until stable*	24 hours with bathroom privileges	8 weeks
IV-V	At least 48 hours*	q 6 hours × 48 hours and every 12 hours until stable*	At least 24 hours with bathroom privileges	12 weeks

\*Additional monitoring should be considered for contrast blush or subcapsular hematoma.

surrounding when to initiate DVT pharmacoprophylaxis can be facilitated using thromboelastography to evaluate hypercoagulability as well as platelet count and platelet mapping to evaluate platelet hyperactivity.

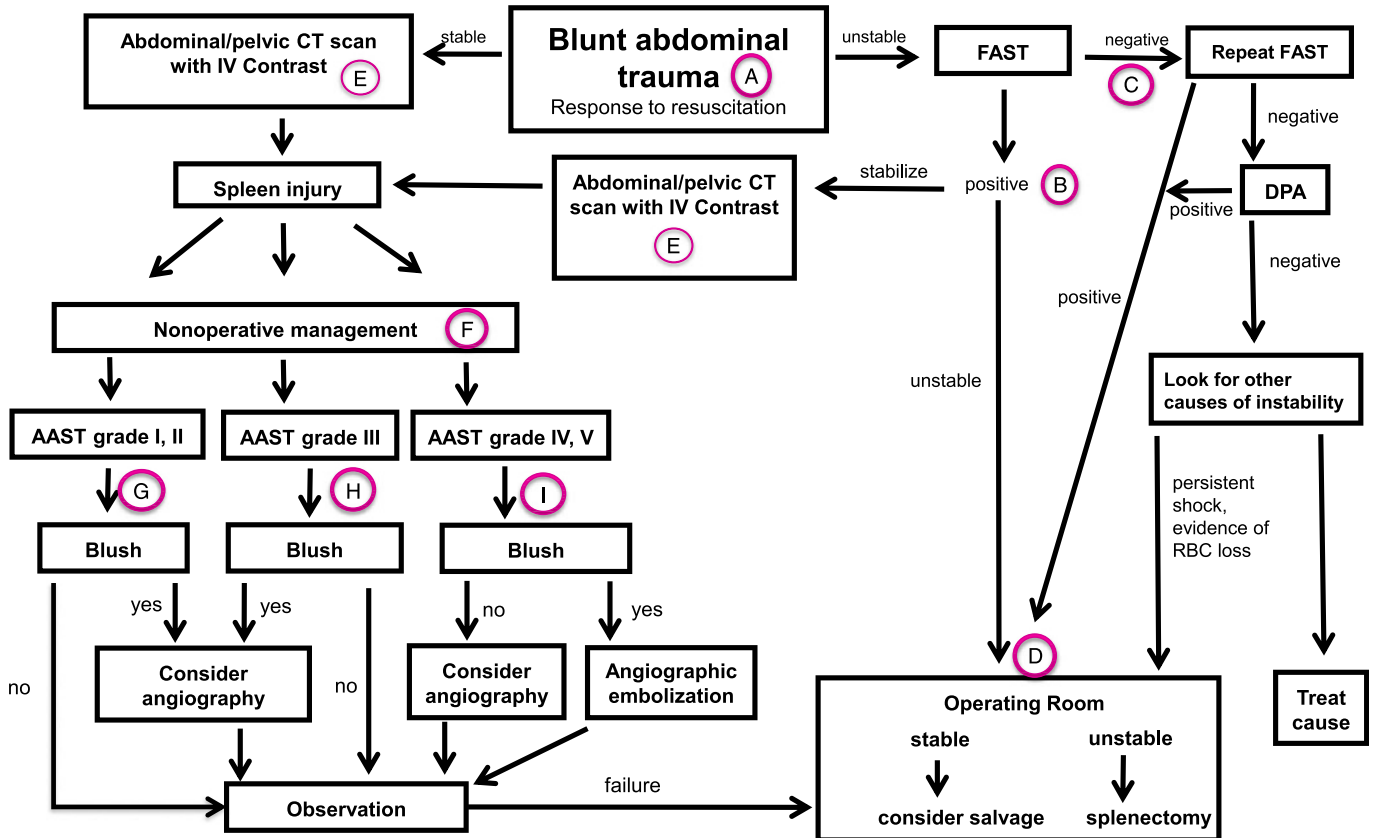
### Hospital Admission and Serial Hemoglobin Evaluation

There are little data available on the optimal length of hospital admission and serial hemoglobin evaluation (Table 3).<sup>7,27</sup> Based on the consensus opinion of this group, we recommend that patients with Grade I injuries be admitted to either the ward or the intensive care unit (ICU) for continuous monitoring. The hemoglobin should be checked every 8 hours for 24 hours. Discharge is recommended if the hemoglobin remains stable (hemoglobin drop of <0.5 g/dL) and no other contraindications exist. All patients with Grade II and Grade III injuries managed nonoperatively should be given strong consideration for ICU admission and continuous monitoring for at least 24 hours. The

hemoglobin should be checked every 6 hours for 24 hours and then every 12 hours until stable (hemoglobin drop <0.5 g/dL). All patients with high-grade injuries (Grades IV and V) undergoing NOM should be admitted to the ICU with continuous monitoring for at least 48 hours. A hemoglobin measurement should be obtained 2 hours after arrival and every 6 hours for 48 hours and continued until at least two stable measurements are obtained. Consideration should be given to additional monitoring for patients with a contrast blush or subcapsular hematoma.<sup>39</sup>

### Bedrest

Guidelines published in 1999 by the American Pediatric Surgical Association (APSA) recommended a period of bedrest equal to the grade of injury plus one in patients undergoing NOM of splenic injury.<sup>37</sup> A recent report has suggested that most US centers tend to follow a shorter period of bedrest than the APSA guidelines indicate.<sup>56</sup> One study in adults in a single center indicated that the day of mobilization was not associated



**Figure 1.** Western Trauma Association algorithm for the management of adult blunt splenic injury.

Downloaded from http://journals.lww.com/trauma by V1R9qAgW9905886mofF4d4que17+XidairqwGLXgds55BmRcX on 11/06/2024

with the rate of delayed bleeding in patients undergoing NOM.<sup>57</sup> An abbreviated protocol with a shorter period of bedrest (1 day for Grades I and II and 2 days for Grades III and higher) than that recommended by APSA has been proposed.<sup>58,59</sup> At this time, there is no conclusively demonstrated benefit to a specific period of bedrest in the early NOM of splenic injury, and we recommend no bedrest for patients with Grade I splenic injuries and bedrest for 24 hours with bathroom privileges for patients with splenic injury Grades II to V.

### Return to Activity

The relatively low numbers of bleeding complication that occur after hospital discharge make it impractical to design a randomized trial to examine the optimal time to return to activity after NOM of a splenic injury. Local guidelines are generally based on expert opinion. One survey of the American Association for the Surgery of Trauma members in 2005 indicated that many trauma surgeons recommend that patients with Grade I to Grade II injuries have activity limitations for 4 to 8 weeks.<sup>5</sup> For Grade III to Grade V injuries, most trauma surgeons recommend contact restrictions for more than 8 weeks or until healing is demonstrated by CT or ultrasound.<sup>60</sup> Based on this, we recommend contact restrictions for at least 4 weeks for patients with Grade I injuries, 8 weeks for patients with Grade II and Grade III injuries, and 12 weeks for Grade IV and Grade V splenic injuries managed nonoperatively. Routine postdischarge imaging studies to confirm complete healing in asymptomatic patients has typically not been recommended except in patients with professions involving a high risk for contact.<sup>61</sup>

### Repeat Imaging

It has generally been suggested that follow-up imaging is not necessary for Grade I and Grade II injuries;<sup>62</sup> however, recent data suggest that the incidence of pseudoaneurysm formation even in low-grade injuries may be significant.<sup>63,64</sup> As a result, a repeat CT scan at 48 to 72 hours in Grade II injuries and higher-grade injuries has been recommended to rule out pseudoaneurysm formation.<sup>63</sup> Based on the available data and consensus opinion, in patients with a documented pseudoaneurysm, we strongly recommend consideration of a repeat imaging before hospital discharge.<sup>65</sup> In all other patients with Grade II or higher-grade injuries, a repeat imaging may be considered before hospital discharge to rule out pseudoaneurysm formation. Stronger consideration should be given to high-grade injuries.

### DISCLOSURE

The authors declare no conflicts of interest.

### REFERENCES

- Moore FA, Davis JW, Moore EE Jr, Cocanour CS, West MA, McIntyre RC Jr. Western Trauma Association (WTA) critical decisions in trauma: management of adult blunt splenic trauma. *J Trauma*. 2008;65:1007–1011.
- Mucha P Jr, Daly RC, Farnell MB. Selective management of blunt splenic trauma. *J Trauma*. 1986;26:970–979.
- Malangoni MA, Levine AW, Droegge EA, Aprahamian C, Condon RE. Management of injury to the spleen in adults. Results of early operation and observation. *Ann Surg*. 1984;200:702–705.
- Wesson DE, Filler RM, Ein SH, Shandling B, Simpson JS, Stephens CA. Ruptured spleen—when to operate? *J Pediatr Surg*. 1981;16:324–326.
- Haller JA Jr, Papa P, Drugas G, Colombani P. Nonoperative management of solid organ injuries in children. Is it safe? *Ann Surg*. 1994;219(6):625–628.
- Coburn MC, Pfeifer J, DeLuca FG. Nonoperative management of splenic and hepatic trauma in the multiply injured pediatric and adolescent patient. *Arch Surg*. 1995;130:332–338.
- Stassen NA, Bhullar I, Cheng JD, Crandall ML, Friese RS, Guillaumondegui OD, Jawa RS, Maung AA, Rohs TJ Jr, Sangosanya A, et al. Selective nonoperative management of blunt splenic injury: an Eastern Association for the Surgery of Trauma practice management guideline. *J Trauma Acute Care Surg*. 2012;73:S294–S300.
- Requarth JA, D'Agostino RB Jr, Miller PR. Nonoperative management of adult blunt splenic injury with and without splenic artery embolotherapy: a meta-analysis. *J Trauma*. 2011;71:898–903.
- Zarzur BL, Kozar R, Myers JG, Claridge JA, Scalea TM, Neideen TA, Maung AA, Alarcon L, Corcos A, Kerwin A, Coimbra R. The splenic injury outcomes trial: an American Association for the Surgery of Trauma multi-institutional study. *J Trauma Acute Care Surg*. 2015;79:335–342.
- Mihalik JE, Smith RS, Toevs CC, Putnam AT, Foster JE. The use of contrast-enhanced ultrasound for the evaluation of solid abdominal organ injury in patients with blunt abdominal trauma. *J Trauma Acute Care Surg*. 2012;73:1100–1105.
- Pisters PW, Pachter HL. Autologous splenic transplantation for splenic trauma. *Ann Surg*. 1994;219:225–235.
- Skattum J, Naess PA, Gaarder C. Non-operative management and immune function after splenic injury. *Br J Surg*. 2012;99(Suppl 1):59–65.
- Demetriades D, Scalea TM, Degiannis E, Barmparas G, Konstantinidis A, Massahis J, Inaba K. Blunt splenic trauma: splenectomy increases early infectious complications: a prospective multicenter study. *J Trauma Acute Care Surg*. 2012;72:229–234.
- Gamblin TC, Wall CE Jr, Royer GM, Dalton ML, Ashley DW. Delayed splenic rupture: case reports and review of the literature. *J Trauma*. 2005;1231–1234.
- Marmery H, Shanmuganathan K, Mirvis SE, Richard H 3rd, Sliker C, Miller LA, Haan JM, Witluis D, Scalea TM. Correlation of multidetector CT findings with splenic arteriography and surgery: prospective study in 392 patients. *J Am Coll Surg*. 2008;206:685–693.
- Olthof DC, Joosse P, van der Vlies CH, de Haan RJ, Goslings JC. Prognostic factors for failure of nonoperative management in adults with blunt splenic injury: a systematic review. *J Trauma Acute Care Surg*. 2013;74:546–557.
- Bhullar IS, Frykberg ER, Siragusa D, Chesire D, Paul J, Tepas JJ 3rd, Kerwin AJ. Age does not affect outcomes of nonoperative management of blunt splenic trauma. *J Am Coll Surg*. 2012;214:958–964.
- Miller PR, Croce MA, Bee TK, Malhotra AK, Fabian TC. Associated injuries in blunt solid organ trauma: implications for missed injury in nonoperative management. *J Trauma*. 2002;53:238–242.
- Renzulli P, Gross T, Schnüriger B, Schoepfer AM, Inderbitzin D, Exadaktylos AK, Hoppe H, Candinas D. Management of blunt injuries to the spleen. *Br J Surg*. 2010;97:1696–1703.
- Michailidou M, Velmahos GC, van der Wilden GM, Alam HB, de Moya M, Chang Y. “Blush” on trauma computed tomography: not as bad as we think! *J Trauma Acute Care Surg*. 2012;73:580–584.
- Sabe AA, Claridge JA, Rosenblum DI, Lie K, Malangoni MA. The effects of splenic artery embolization on nonoperative management of blunt splenic injury: a 16-year experience. *J Trauma*. 2009;67:565–572.
- Velmahos GC, Zacharias N, Emhoff TA, Feeney JM, Hurst JM, Crookes BA, Harrington DT, Gregg SC, Brotman S, Burke PA, Davis KA, Gupta R, Winchell RJ, Desjardins S, Alouidor R, Gross RI, Rosenblatt MS, Schulz JT, Chang Y. Management of the most severely injured spleen: a multicenter study of the Research Consortium of New England Centers for Trauma (ReCONNECT). *Arch Surg*. 2010;145:456–460.
- Duchesne JC, Simmons JD, Schmieg RE Jr, McSwain NE Jr, Bellows CF. Proximal splenic angioembolization does not improve outcomes in treating blunt splenic injuries compared with splenectomy: a cohort analysis. *J Trauma*. 2008;65:1346–1351.
- Skattum J, Naess PA, Eken T, Gaarder C. Refining the role of splenic angiographic embolization in high-grade splenic injuries. *J Trauma Acute Care Surg*. 2013;74:100–103.
- Miller PR, Chang MC, Hoth JJ, Mowery NT, Hildreth AN, Martin RS, Holmes JH, Meredith JW, Requarth JA. Prospective trial of angiography and embolization for all grade III to V blunt splenic injuries: nonoperative management success rate is significantly improved. *J Am Coll Surg*. 2014;218:644–648.

26. Bhullar IS, Frykberg ER, Siragusa D, Chesire D, Paul J, Tepas JJ III, Kerwin AJ. Selective angiographic embolization of blunt splenic traumatic injuries in adults decreased failure rate of nonoperative management. *J Trauma*. 2012; 72:1127–1134.
27. Brault-Noble G, Charbit J, Chardon P, Barral L, Guillon F, Taourel P, Capdevila X, Millet I. Age should be considered in the decision making of prophylactic splenic angioembolization in nonoperative management of blunt splenic trauma: a study of 208 consecutive civilian trauma patients. *J Trauma Acute Care Surg*. 2012;73:1213–1220.
28. McCray VW, Davis JW, Lemaster D, Parks SN. Observation for nonoperative management of the spleen: how long is long enough? *J Trauma*. 2008;65: 1354–1358.
29. Bhullar IS, Frykberg ER, Tepas JJ 3rd, Siragusa D, Loper T, Kerwin AJ. At first blush: absence of computed tomography contrast extravasation in Grade IV or V adult blunt splenic trauma should not preclude angioembolization. *J Trauma Acute Care Surg*. 2013;74:105–111.
30. Gaarder C, Dormagen JB, Eken T, Skaga NO, Klow NE, Pillgram-Larsen J, Buanes T, Naess PA. Nonoperative management of splenic injuries: improved results with angioembolization. *J Trauma*. 2006;61:192–198.
31. Hagiwara A, Fukushima H, Murata A, Matsuda H, Shimazaki S. Blunt splenic injury: usefulness of transcatheter arterial embolization in patients with a transient response to fluid resuscitation. *Radiology*. 2005;235:57–64.
32. Harbrecht BG, Ko SH, Watson GA, Forsythe RM, Rosengart MR, Peitzman AB. Angiography for blunt splenic trauma does not improve the success rate of nonoperative management. *J Trauma*. 2007;63:44–49.
33. van der Vlies CH, Saltzherr TP, Reekers JA, Ponsen KJ, van Delden OM, Goslings JC. Failure rate and complications of angiography and embolization for abdominal and pelvic trauma. *J Trauma Acute Care Surg*. 2012; 73:1208–1212.
34. Haan JM, Biffl W, Knudson MM, Davis KA, Oka T, Majercik S, Dicker R, Marder S, Scalea TM. Splenic embolization revisited: a multicenter review. *J Trauma*. 2004;56:542–547.
35. Smith HE, Biffl WL, Majercik SD, Jednacz J, Lambiase R, Cioffi WG. Splenic artery embolization: have we gone too far? *J Trauma*. 2006;61: 541–544.
36. Schnüriger B, Inaba K, Konstantinidis A, Lustenberger T, Chan LS, Demetriades D. Outcomes of proximal versus distal splenic artery embolization after trauma: a systematic review and meta-analysis. *J Trauma*. 2011;70: 252–260.
37. Stylianos S. Evidence-based guidelines for resource utilization in children with isolated spleen or liver injury. The APSA trauma committee. *J Pediatr Surg*. 2000;35:164–167.
38. Ekeh AP, McCarthy MC, Woods RJ, Haley E. Complications arising from splenic embolization after blunt splenic trauma. *Am J Surg*. 2005;189: 335–339.
39. Zarzaar BL, Kozar RA, Fabian TC, Coimbra R. A survey of American Association for the Surgery of Trauma member practices in the management of blunt splenic injury. *J Trauma*. 2011;70:1026–1031.
40. Cullingford GL, Watkins DN, Watts AD, Mallon DF. Severe late post-splenectomy infection. *Br J Surg*. 1991;78:716–721.
41. Ley EJ, Singer MB, Clond MA, Johnson T, Bukur M, Chung R, Margulies DR, Salim A. Long-term effect of trauma splenectomy on blood glucose. *J Surg Res*. 2012;177:152–156.
42. Wu SC, Fu CY, Muo CH, Chang YJ. Splenectomy in trauma patients is associated with an increased risk of postoperative type II diabetes: a nationwide population-based study. *Am J Surg*. 2014;208:811–816.
43. O'Keefe T. The spleen as a diabetic organ; rethinking trauma splenectomy. *J Surg Res*. 2014;186:103–104.
44. Watters JM, Sambasivan CN, Zink K, Kremenevskiy I, Englehart MS, Underwood SJ, Schreiber MA. Splenectomy leads to a persistent hypercoagulable state after trauma. *Am J Surg*. 2010;199:646–651.
45. Pimpl W, Dapunt O, Kaindl H, Thalhamer J. Incidence of septic and thromboembolic-related deaths after splenectomy in adults. *Br J Surg*. 1989;76:517–521.
46. Sun LM, Chen HJ, Jeng LB, Li TC, Wu SC, Kao CH. Splenectomy and increased subsequent cancer risk: a nationwide population-based cohort study. *Am J Surg*. 2015;210:243–251.
47. Hafiz S, Desale S, Sava J. The impact of solid organ injury management on the US health care system. *J Trauma Acute Care Surg*. 2014;77:310–314.
48. Shatz DV. Vaccination practices among North American trauma surgeons in splenectomy for trauma. *J Trauma*. 2002;53:950–956.
49. Shatz DV, Romero-Steiner S, Elie CM, et al. Antibody responses in post-splenectomy trauma patients receiving the 23-valent pneumococcal polysaccharide vaccine at 14 versus 28 days postoperatively. *J Trauma*. 2002;53:1037–1042.
50. Shatz DV, Schinsky MF, Pais LB, et al. Antibody responses in post-splenectomy trauma patients receiving the 23-valent pneumococcal polysaccharide vaccine at 1 versus 7 versus 14 days after splenectomy. *J Trauma*. 1998;44(6):760–766.
51. CDC vaccination schedule recommendations based on age. Available at: <http://www.cdc.gov/vaccines/schedules/hcp/imz/adult-shell.html>. Accessed January 22, 2015.
52. Firstenberg MS, Plaisier B, Newman JS, Malangoni MA. Successful treatment of delayed splenic rupture with splenic artery embolization. *Surgery*. 1998;123:584–586.
53. Liu PP, Liu HT, Hsieh TM, Huang CY, Ko SF. Nonsurgical management of delayed splenic rupture after blunt trauma. *J Trauma Acute Care Surg*. 2012; 72:1019–1023.
54. Eberle BM, Schnüriger B, Inaba K, Cestero R, Kobayashi L, Barmparas G, Oliver M, Demetriades D. Thromboembolic prophylaxis with low-molecular-weight heparin in patients with blunt solid abdominal organ injuries undergoing nonoperative management: current practice and outcomes. *J Trauma*. 2011;70:141–146.
55. Joseph B, Pandit V, Harrison C, Lubin D, Kulvatunyou N, Zangbar B, Tang A, O'Keefe T, Green DJ, Gries L, Friese RS, Rhee P. Early thromboembolic prophylaxis in patients with blunt solid abdominal organ injuries undergoing nonoperative management: is it safe? *Am J Surg*. 2015;209:194–198.
56. Dodgion CM, Gosain A, Rogers A, St Peter SD, Nichol PF, Ostlie DJ. National trends in pediatric blunt spleen and liver injury management and potential benefits of an abbreviated bed rest protocol. *J Pediatr Surg*. 2014: 1004–1008.
57. London JA, Parry L, Galante J, Battistella F. Safety of early mobilization of patients with blunt solid organ injuries. *Arch Surg*. 2008;143:972–976.
58. St Peter SD, Sharp SW, Snyder CL, Sharp RJ, Andrews WS, Murphy JP, Islam S, Holcomb GW 3rd, Ostlie DJ. Prospective validation of an abbreviated bedrest protocol in the management of blunt spleen and liver injury in children. *J Pediatr Surg*. 2011;46:173–177.
59. St Peter SD, Aguayo P, Juang D, Sharp SW, Snyder CL, Holcomb GW 3rd, Ostlie DJ. Follow-up of prospective validation of an abbreviated bedrest protocol in the management of blunt spleen and liver injury in children. *J Pediatr Surg*. 2013;48:2437–2441.
60. Fata P, Robinson L, Fakhry SM. A survey of EAST member practices in blunt splenic injury: a description of current trends and opportunities for improvement. *J Trauma*. 2005;59:836–841.
61. Olthoff DC, van der Vlies CH, Joosse P, van Delden OM, Jurkovich GJ, Goslings JC; on behalf of the PYTHIA Collaboration Group. Consensus strategies for the nonoperative management of patients with blunt splenic injury: a Delphi study. *J Trauma Acute Care Surg*. 2013;74:1567–1574.
62. Haan JM, Boswell S, Stein D, Scalea TM. Follow-up abdominal CT is not necessary in low-grade splenic injury. *Am Surg*. 2007;73:13–18.
63. Muroya T, Ogura H, Shimizu K, Tasaki O, Kuwagata Y, Fuse T, Nakamori Y, Ito Y, Hino H, Shimazu T. Delayed formation of splenic pseudoaneurysm following nonoperative management in blunt splenic injury: multi-institutional study in Osaka, Japan. *J Trauma Acute Care Surg*. 2013;75:417–420.
64. Leeper WR, Leeper TJ, Ouellette D, Moffat B, Sivakumaran T, Charyk-Stewart T, Kribs S, Parry NG, Gray DK. Delayed hemorrhagic complications in the nonoperative management of blunt splenic trauma: early screening leads to a decrease in failure rate. *J Trauma Acute Care Surg*. 2014;76: 1349–1353.
65. Weinberg JA, Magnotti LJ, Croce MA, Edwards NM, Fabian TC. The utility of serial computed tomography imaging of blunt splenic injury: still worth a second look? *J Trauma*. 2007;62:1143–1147.
66. Moore EE, Cogbill TH, Jurkovich GJ, Shackford SR, Malangoni MA, Champion HR. Organ injury scaling: spleen and liver (1994 revision). *J Trauma*. 1995;38:323–324.