

# Western Trauma Association Critical Decisions in Trauma: Diagnosis and management of duodenal injuries

**Ajai Malhotra, MD, Walter L. Biffi, MD, Ernest E. Moore, MD, Martin Schreiber, MD,  
Roxie A. Albrecht, MD, Mitchell Cohen, MD, Martin Croce, MD, Riyad Karmy-Jones, MD,  
Nicholas Namias, MD, Susan Rowell, MD, David V. Shatz, MD,  
and Karen J. Brasel, MD, Richmond, Virginia**

## AAST Continuing Medical Education Article

### Accreditation Statement

This activity has been planned and implemented in accordance with the Essential Areas and Policies of the Accreditation Council for Continuing Medical Education through the joint providership of the American College of Surgeons and the American Association for the Surgery of Trauma. The American College of Surgeons is accredited by the ACCME to provide continuing medical education for physicians.

### AMA PRA Category 1 Credits™

The American College of Surgeons designates this journal-based CME activity for a maximum of 1 *AMA PRA Category 1 Credit*™. Physicians should claim only the credit commensurate with the extent of their participation in the activity.

Of the *AMA PRA Category 1 Credit*™ listed above, a maximum of 1 credit meets the requirements for self-assessment.

Credits can only be claimed online



AMERICAN COLLEGE OF SURGEONS

*Inspiring Quality:*

*Highest Standards, Better Outcomes*

100+ years

### Objectives

After reading the featured articles published in the *Journal of Trauma and Acute Care Surgery*, participants should be able to demonstrate increased understanding of the material specific to the article. Objectives for each article are featured at the beginning of each article and online. Test questions are at the end of the article, with a critique and specific location in the article referencing the question topic.

### Claiming Credit

To claim credit, please visit the AAST website at <http://www.aast.org/> and click on the "e-Learning/MOC" tab. You must read the article, successfully complete the post-test and evaluation. Your CME certificate will be available immediately upon receiving a passing score of 75% or higher on the post-test. Post-tests receiving a score of below 75% will require a retake of the test to receive credit.

### System Requirements

The system requirements are as follows: Adobe® Reader 7.0 or above installed; Internet Explorer® 7 and above; Firefox® 3.0 and above, Chrome® 8.0 and above, or Safari™ 4.0 and above.

### Questions

If you have any questions, please contact AAST at 800-789-4006. Paper test and evaluations will not be accepted.

### Disclosure Information

In accordance with the ACCME Accreditation Criteria, the American College of Surgeons, as the accredited provider of this journal activity, must ensure that anyone in a position to control the content of *J Trauma Acute Care Surg* articles selected for CME credit has disclosed all relevant financial relationships with any commercial interest. Disclosure forms are completed by the editorial staff, associate editors, reviewers, and all authors. The ACCME defines a 'commercial interest' as "any entity producing, marketing, re-selling, or distributing health care goods or services consumed by, or used on, patients." "Relevant" financial relationships are those (in any amount) that may create a conflict of interest and occur within the 12 months preceding and during the time that the individual is engaged in writing the article. All reported conflicts are thoroughly managed in order to ensure any potential bias within the content is eliminated. However, if you perceive a bias within the article, please report the circumstances on the evaluation form.

Please note we have advised the authors that it is their responsibility to disclose within the article if they are describing the use of a device, product, or drug that is not FDA approved or the off-label use of an approved device, product, or drug or unapproved usage.

### Disclosures of Significant Relationships with Relevant Commercial Companies/Organizations by the Editorial Staff

Ernest E. Moore, Editor: PI, research support and shared U.S. patents Haemonetics; PI, research support, TEM Systems, Inc. Ronald V. Maier, Associate editor: consultant, consulting fee, LFB Biotechnologies. Associate editors: David Hoyt and Steven Shackford have nothing to disclose. Editorial staff: Jennifer Crebs, Jo Fields, and Angela Sauaia have nothing to disclose.

### Author Disclosures

The authors have nothing to disclose.

### Reviewer Disclosures

The reviewers have nothing to disclose.

### Cost

For AAST members and *Journal of Trauma and Acute Care Surgery* subscribers there is no charge to participate in this activity. For those who are not a member or subscriber, the cost for each credit is \$25.

## DUODENAL INJURIES

The duodenum is primarily a retroperitoneal structure and is relatively well protected; consequently, injuries to the duodenum are uncommon, representing less than 2% of all abdominal injuries. Although uncommon, the consequences of duodenal injury can be devastating. The reasons for this include the following: (1) Anatomic: The duodenum lies near multiple major vascular structures, and hence, injury to the duodenum commonly accompanies major vascular injuries with resultant hemorrhagic shock. (2) Physiologic: The duodenum is intimately attached to the pancreas, and a combined pancreaticoduodenal injury is common. The powerful digestive enzymes produced by the pancreas can lead to devastating infection and necrosis within the retroperitoneum. (3) Healing: Duodenal repairs have a higher incidence of failure as compared with other parts of the intestine. There is not one secure method of repair that can be reliably used with a high expectation of success. Failure of the duodenal repair can lead to leakage of up to 6 L of combined gastric, biliary, and pancreatic juices, causing major fluid and electrolyte disturbances and severe nutritional depletion. For these reasons, the approach to these injuries requires complex decision making regarding the timing and type(s) of repairs that should be undertaken for a specific injury.<sup>1</sup>

## DIAGNOSIS

Unstable patients with suspected intra-abdominal injuries should undergo emergent laparotomy, while hemodynamically normal patients with significant blunt trauma generally undergo computed tomography (CT). Based on these two common scenarios, a duodenal injury may be diagnosed either intraoperatively in the unstable patient or by CT in the stable patient. Since CT can miss an early hollow viscus (e.g., duodenal) injury (before periduodenal inflammation becomes apparent), a third scenario occurs when the duodenal injury is detected more than 24 hours after the trauma, either by CT scan or intraoperatively. In such situations, there may be significant local contamination in the area resulting in signs of sepsis. The approach to the duodenal injury in these three scenarios—unstable patient at laparotomy, stable patient with early diagnosis of the duodenal injury, and septic patient with delayed diagnosis of the duodenal injury—will be quite different, as will be the expected outcomes.

## ANATOMIC GRADING OF INJURY

The organ injury scale developed by the American Association for the Surgery of Trauma (AAST) is most commonly used (Table 1).<sup>2</sup> Anatomic grading provides a useful tool to

assess the degree of injury and plan the repairs accordingly but does not correlate well with outcomes such as mortality.<sup>3–5</sup> Although the same anatomic injury may be repaired at a different time and the nature of repair may be different depending on physiology, hemodynamics, degree of contamination, and presence or absence of sepsis, the repair for a specific anatomic injury in the ideal situation serves as the starting point with modifications based on physiologic factors.

## MANAGEMENT ALGORITHM

### Assessment of Patient Stability

In any situation where a laparotomy for trauma is performed, the decision to proceed with immediate definitive repair versus damage-control and delayed repair is an important one (Fig. 1). This principle is valid for duodenal injuries as well. The close proximity of the duodenum to major vascular structures and the pancreas and the commonality of combined injuries result in the frequent finding of hemorrhagic shock (most commonly in penetrating trauma) or complex injuries requiring complex reconstruction. If the patient is demonstrating evidence of severe physiologic compromise in the form of acidosis, coagulopathy, and hypothermia, the decision to proceed with damage control should be made early.<sup>6</sup> In these scenarios, hemorrhage should be controlled, and simple closure of the duodenum should be performed. The bile duct may be ligated or, if possible, cannulated and externally drained.<sup>3</sup> The focus is less on the injury and more on obtaining control of contamination and transferring the patient to the intensive care unit for resuscitation. In massive injuries with severe destruction of the duodenum (discussed later), it may not be possible to control all contamination. In such cases, it is appropriate to place drains and leave the abdomen open. If the patient is deemed stable or has undergone damage-control surgery followed by resuscitation in the intensive care unit, the next step is the assessment of the duodenal injury to plan appropriate repair.

If a stable patient undergoes CT scan and there is evidence of duodenal injury, there must be further evaluation. Periduodenal fluid or stranding should be further evaluated with either a repeat CT scan with duodenal contrast or a fluoroscopic study of the duodenum with enteral contrast, to exclude contrast extravasation, which would mandate laparotomy. Laparoscopy is not recommended because a full Kocher maneuver must be performed and a small laceration may be missed. Laparotomy is also an option but may not be necessary in a stable patient with simple duodenal hematoma. The magnitude of the imaging abnormality and the patient's condition dictate the approach. If the initial CT scan shows

Submitted: August 23, 2015, Revised: August 25, 2015, Accepted: September 2, 2015.

From the Medical College of Virginia (A.M.), Richmond, Virginia; Denver Health Medical Center (W.L.B., E.E.M.), Denver, Colorado; Oregon Health and Science University (M.S., S.R., K.J.B.); and Legacy Emmanuel Medical Center (R.K.-J.), Portland, Oregon; University of Oklahoma (R.A.A.), Oklahoma City, Oklahoma; University of California, San Francisco (M.Co.), San Francisco; and University of California-Davis (D.V.S.), Sacramento, California; University of Tennessee (M.Cr.), Memphis, Tennessee; University of Miami (N.N.), Miami, Florida.

This was presented at the 44th annual meeting of the Western Trauma Association, March 2–7, 2014, in Steamboat Springs, Colorado.

Address for reprints: Ajai Malhotra, MD, Division of Acute Care Surgery, Department of Surgery, University of Vermont Medical Center 111 Colchester Ave. 320FL4, VT 05401, VA; email: Ajai.Malhotra@uvmhealth.org.

DOI: 10.1097/TA.0000000000000870

**TABLE 1. AAST Organ Injury Scale for Duodenum**

Grade*	Type of Injury	Description
I	Hematoma	Involving single portion of duodenum
	Laceration	Partial thickness—no perforation
II	Hematoma	Involving more than one portion of duodenum
	Laceration	Disruption by <50% of circumference
III	Laceration	Disruption by 50–75% of circumference of D2
		Disruption by 75–100% of circumference of D1/D3/D4
IV	Laceration	Disruption by >75% of circumference involving ampulla or distal common bile duct
V	Laceration	Massive destruction of duodenopancreatic complex
	Vascular	Devascularization of duodenum

From Moore et al.<sup>2</sup> Reprinted with permission from Wolters Kluwer Health/Lippincott Williams & Wilkins.

\*Advance one grade for multiple injuries up to Grade III. D1, first portion of duodenum; D2, second portion of duodenum; D3, third portion of duodenum; D4, fourth portion of duodenum.

periduodenal air in addition to fluid or stranding, the safest (most conservative) approach is immediate laparotomy.

AAST Grade I	Hematoma	Involving one portion of the duodenum
	Laceration	Partial thickness with no transmural perforation

**Assessment and Management of Duodenal Injury**

If a Grade I hematoma is diagnosed by CT scan, initial management is expectant, with nasogastric tube decompression and withholding oral intake. Occasionally, a duodenal hematoma may progress to duodenal obstruction over hours to days.<sup>7</sup> In general, nonoperative management is appropriate for up to 14 days.<sup>8</sup> If the obstruction is not resolved by then, operative intervention with drainage of the hematoma and simple repair should be performed.<sup>3</sup> If the injury is diagnosed at laparotomy, a laceration should be repaired. In case of a hematoma encountered intraoperatively, if the lumen is not compromised, nothing needs to be done, but if the lumen is compromised by 50% or greater, it should be drained by an incision on the external surface, preferably avoiding luminal entry, and simple repair. Meticulous hemostasis is essential before closure to avoid recurrence. In case the hematoma oc-

AAST Grade II	Hematoma	Involving more than one portion of the duodenum
	Laceration	Full thickness < 50% circumference (duct/ampulla—intact)

cupies more than 75% of the lumen, consideration should be given to performing a gastrojejunostomy to avoid delayed duodenal obstruction.<sup>3</sup>

Grade II hematomas are managed in the same way as Grade I hematomas. Grade II lacerations managed early after injury should be repaired using simple, tension-free techniques in the transverse orientation provided that the edges are clean and viable and there is minimal contamination.<sup>3</sup> The majority (55–85%) of duodenal injuries can be managed by this technique.<sup>4,5,9,10</sup> A transverse repair ensures that the lumen of the duodenum is not narrowed. However, because of the fixed nature of the duodenal loop, a tension-free transverse closure

AAST Grade III	Laceration	50–75% circumference of D2 (duct/ampulla—intact)
		50–100% circumference of D1/D3/D4

may not be possible. In such situations or if there is significant contamination or delayed management, injuries may be managed as in Grade III injuries.

Tension-free repair is essential. Transverse repair is preferred to avoid luminal narrowing. For more extensive lacerations, duodenal mobilization with duodenoduodenostomy may be necessary. If tension-free repair is not possible and the defect is less than 50% of the duodenal circumference, the edges of the duodenal injury should be debrided back to healthy bleeding tissue, and a limb of jejunum brought up to the defect to create a Roux-en-Y duodenojejunostomy. This is a fairly robust repair and can tolerate moderate contamination in the field.<sup>3</sup> For more extensive defects, the duodenum must be closed, and a Roux-en-Y duodenojejunostomy must be created to the proximal duodenum. If the injury is to the first portion or proximal second portion of the duodenum, another alternative,

AAST Grade IV	Laceration	75–100% circumference of D2 (ducts/ampulla—intact)
	Laceration	D2 (bile duct/ampulla—not intact)

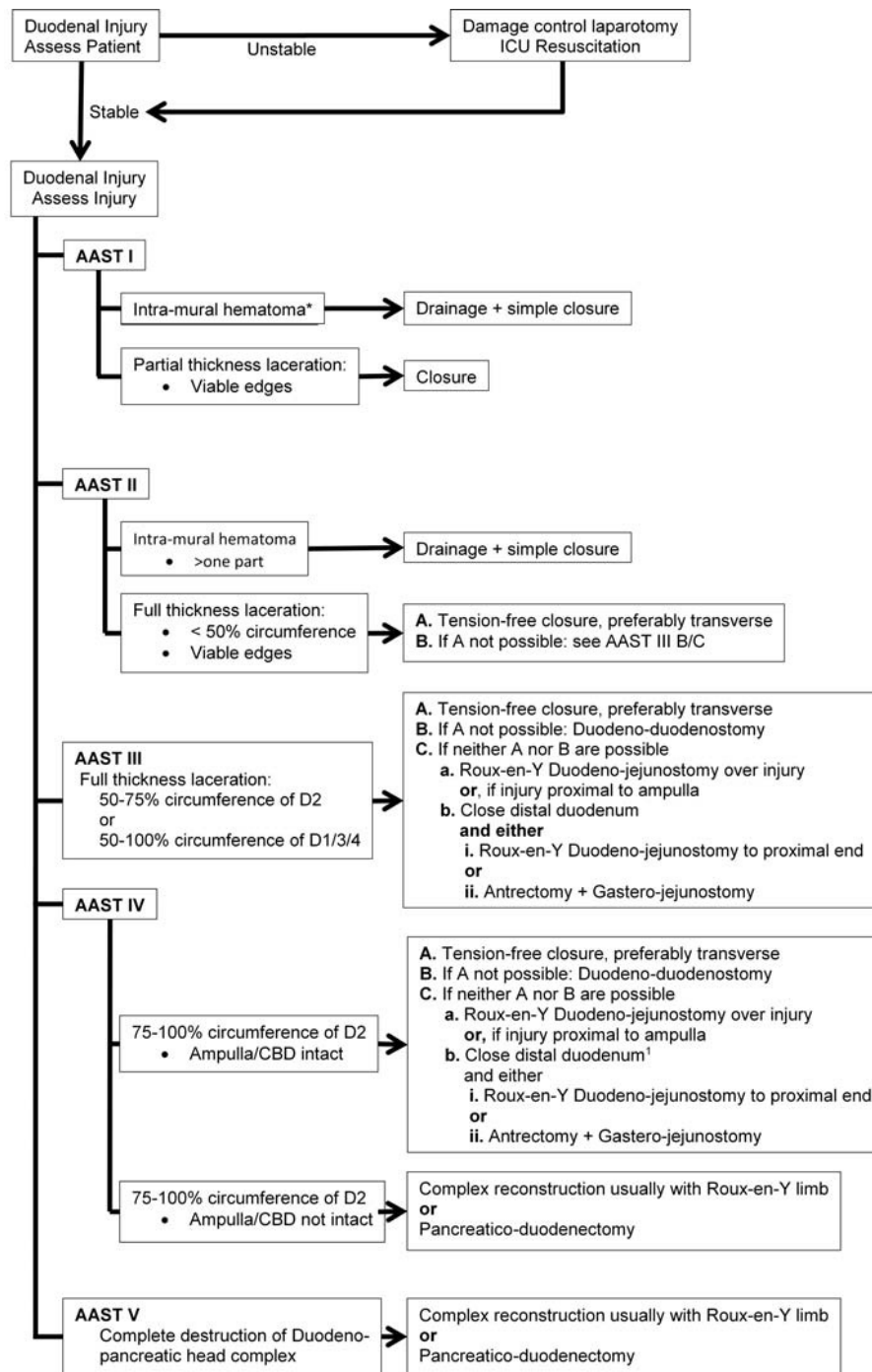
after closing the distal duodenum (containing the ampulla), is to perform a formal antrectomy and reconstruct with a gastrojejunostomy (Billroth II).<sup>3</sup>

In situations where the injury is a near-complete laceration and the bile duct and ampulla are spared, the injury should be approached similarly to AAST Grade III (discussed earlier).

AAST Grade V	Laceration	Massive destruction of duodenopancreatic complex
	Vascular	Devascularization of the duodenum

If the injury to D2 involves the bile duct and/or the ampulla, more complex reconstruction/resection will be required as in AAST Grade V (discussed later).

Grade V injuries are devastating, and the patients usually present in hemorrhagic shock requiring damage control. If the patient survives and is brought back for reconstructive surgery, complex repairs and/or resections may be necessary. If the duodenum can be repaired using reconstructive techniques as described for Grade III injuries, then the bile duct may be replanted into the duodenum<sup>11</sup> or anastomosed to a



\*If detected by CT and there is no other indication to operate observe with gastric decompression. If does not resolve during observation then operate and manage as AAST I above.

**Figure 1.** Proposed algorithm for the management of duodenal injuries. AAST: American Association for the Surgery for Trauma.

Roux-en-Y jejunal loop.<sup>12</sup> The same loop can be used to repair/reconstruct the duodenum. If the duodenum cannot be repaired and/or the pancreatic head is destroyed, a pancreaticoduodenectomy (Whipple procedure) will be necessary.<sup>3</sup> Outcomes of

pancreaticoduodenectomy are improved at high-volume centers with high-volume surgeons.<sup>13</sup> If pancreaticoduodenectomy is necessary, it is prudent to perform damage control and bring the patient back for reconstruction later, when he or she is

resuscitated and physiologically optimized.<sup>14</sup> Consultation with a surgeon colleague who has experience or additional training in this area may be helpful.

## ANCILLARY PROCEDURES

### Duodenal Diversion

Three types of duodenal diversions have been practiced.

#### Berne's Duodenal Diverticulization

This technique, popularized by Berne for complex duodenal injuries, consists of primary repair of the duodenal injury, antrectomy with vagotomy, closure of the duodenal stump over a decompressive tube duodenostomy (end duodenostomy), placement of a T-tube in the common bile duct, and periduodenal drains.<sup>15,16</sup> The principle behind this very involved procedure is to completely divert all gastric and biliary secretions duodenum. The procedure has been criticized for its complexity and physiologic disruption and is primarily of historical interest.

#### Pyloric Exclusion

Originally described at Ben-Taub Hospital in Houston as a less complex and disruptive procedure than Berne's diverticulization, this procedure achieves the same aim with equivalent clinical outcomes.<sup>17,18</sup> It consists of primary repair of the duodenum, closure of the pylorus from within through a gastrotomy, and completing the procedure by performing a gastrojejunostomy at the site of the gastrotomy. The need for the gastrojejunostomy has been questioned since the pylorus spontaneously opens in 3 weeks in 90% of the patients when it has been closed with absorbable suture from within.<sup>19</sup> When a gastrojejunostomy is performed, the main long-term complication is anastomotic ulcer at the site.<sup>20</sup> The value of pyloric exclusion has been questioned in recent reviews, and its use should be highly individualized.<sup>21</sup>

#### Tube Duodenostomies

Another even less complicated method of diversion is tube duodenostomy. Many surgeons feel that a lateral or end tube duodenostomy near the site of the injury has a high rate of failure, but where the degree of inflammation precludes any other approach, such as with delayed presentation, they may prove successful. While techniques may fall into disfavor, knowledge of historical techniques may be helpful. There is also some support for placing decompressing tubes within the lumen of the duodenum either antegrade from the stomach or retrograde from the jejunum.<sup>3,22,23</sup>

#### Current Status

The need for any form of diversion—Berne's, pyloric exclusion, or tube duodenostomy—has been questioned in multiple studies,<sup>3,4,10,24–27</sup> although there is no definitive study that proves the utility of any form of diversion. While the complete Berne's diverticulization is almost never used, a modified version without the T-tube and vagotomy may be useful in very rare instances where the duodenal repair is

tenuous, there is significant contamination, and the vascular supply of the duodenum may be compromised. Pyloric exclusion should be considered in situations of a tenuous duodenal repair. Adjunctive gastrojejunostomy is standard, but in some centers, it is omitted without adverse sequelae.<sup>19</sup> Finally, tube decompression by either an antegrade or retrograde duodenal tube may be of benefit in situations of a tenuous repair with mild contamination.<sup>3</sup>

#### Feeding Jejunostomy

The benefits of early enteral nutrition after major trauma are well established.<sup>28</sup> A jejunal feeding tube is a very good way of accomplishing early enteral feeding. In addition, one of the complications following duodenal injury repair, irrespective of the method of repair, is the formation of a duodenal and/or pancreatic fistula. In these scenarios, the availability of distal feeding access is of great benefit.<sup>3</sup>

#### Periduodenal Drains

The use of periduodenal drains is debated, and there is no Level I evidence supporting routine use or routine nonuse. We do not feel drains should be routinely placed for repair of Grade I or II injuries. Drains should be placed in any case in which repair is felt to be tenuous enough that a "protective" maneuver such as pyloric exclusion is used. For Grade III injuries, it is a matter of preference. The advantage is that in case of a leak, there will be a controlled fistula. If a drain is to be used, a closed suction drain is superior to other types of drains.

## SUMMARY

Duodenal injuries are uncommon but can be devastating. Almost 80% of the injuries are from penetrating mechanisms. Repair of injuries should only be performed in stable patients. The anatomy of the injury, patient status, and degree of contamination should be carefully evaluated in deciding the type of repair that will be most appropriate. The large majority of the injuries can be repaired by simple techniques with attention to good vascularity and tension-free repairs. A small minority of the injuries require complex reconstruction. The outcome of patients with duodenal injuries is more dependent on associated injuries and the timing of repair rather than the anatomy of the injury or the type of repair performed. Duodenal fistula and obstruction are the two principal sources of morbidity.

## REFERENCES

1. Biffi WL. Duodenum and pancreas. In: Mattox KL, Moore EE, Feliciano DV, eds. *Trauma*. 7th ed. New York, NY: McGraw-Hill; 2012.
2. Moore E, Cogbill TH, Malangoni MA, Jurkovich GJ, Champion HR, Gennarelli TA, McAninch JW, Pachter HL, Shackford SR, Trafton PG. Organ injury scaling II: pancreas, duodenum, small bowel, colon, and rectum. *J Trauma*. 1990;30(11):1427–1429.
3. Carrillo EH, Richardson JD, Miller FB. Evolution in the management of duodenal injuries. *J Trauma*. 1996;40(6):1037–1045.
4. Cogbill TH, Moore EE, Feliciano DV, Hoyt DB, Jurkovich GJ, Morris JA, Mucha P Jr, Ross SE, Strutt PJ, Moore FA, et al. Conservative management of duodenal trauma: a multicenter perspective. *J Trauma*. 1990;30(12):1469–1475.
5. Kline G, Lucas CE, Ledgerwood AM, Saxe JM. Duodenal organ injury severity and outcome. *Am Surg*. 1994;60(7):500–504.
6. Rotondo MF, Schwab CW, McGonigal MD, Phillips GR 3rd, Fruchterman TM, Kauder DR, Latenser BA, Angood PA. "Damage control": an

- approach for improved survival in exsanguinating penetrating abdominal injuries. *J Trauma*. 1993;35(3):375–382.
7. Touloukian RJ. Protocol for the nonoperative treatment of obstructing intramural duodenal hematoma during childhood. *Am J Surg*. 1983;145(3):330–334.
  8. Jewett TC Jr, Caldarola V, Karp MP, Allen JE, Cooney DR. Intramural hematoma of the duodenum. *Arch Surg*. 1988;123(1):54–58.
  9. Asensio JA, Feliciano DV, Britt LD, Kerstein MD. Management of duodenal injuries. *Curr Probl Surg*. 1993;30(11):1023–1093.
  10. Snyder W, Weigelt JA, Watkins WL, Bietz DS. The surgical management of duodenal trauma. *Arch Surg*. 1980;115(4):422–429.
  11. Longmire W Jr, McArthur MS. Occult injuries of the liver bile duct and pancreas after blunt abdominal trauma. *Am J Surg*. 1973;125(6):661–666.
  12. Fish J, Johnson GL. Rupture of the duodenum following blunt trauma: report of a case with avulsion of the papilla of Vater. *Ann Surg*. 1965;162(5):917–919.
  13. Donahue TR, Reber HA. Surgical management of pancreatic cancer—pancreaticoduodenectomy. *Semin Oncol*. 2015;42(1):98–109.
  14. Thompson CM, Shalhub S, DeBoard ZM, Maier RV. Revisiting the pancreaticoduodenectomy for trauma: a single institution's experience. *J Trauma Acute Care Surg*. 2013;75(2):225–228.
  15. Berne CJ, Donovan AJ, Hagen WE. Combined duodenal pancreatic trauma: the role of gastrojejunostomy. *Arch Surg*. 1968;96(5):712–722.
  16. Berne CJ, Donovan AJ, White EJ, Yellin AE. Duodenal “diverticulization” for duodenal and pancreatic injury. *Am J Surg*. 1974;127(5):503–507.
  17. Vaughan GD III, Frazier OH, Graham DY, Mattox KL, Petmecky FF, Jordan GL Jr. The use of pyloric exclusion in the management of severe duodenal injuries. *Am J Surg*. 1977;134(6):785–790.
  18. Martin TD, Feliciano DV, Mattox KL, Jordan GL Jr. Severe duodenal injuries: treatment with pyloric exclusion and gastrojejunostomy. *Arch Surg*. 1983;118(5):631–635.
  19. Ginzburg E, Martin L, Carrillo E, et al. *Pyloric Exclusion: Is Concomitant Gastrojejunostomy Necessary? Abstract. 26th Annual Scientific Meeting*. Alta, WY: The Western Trauma Association; 1996.
  20. Buck JR, Sorensen VJ, Fath JJ, Horst HM, Obeid FN. Severe pancreatoduodenal injuries: the effectiveness of pyloric exclusion with vagotomy. *Am Surg*. 1992;58(9):557–560.
  21. Cruvinel Neto J, Pereira BM, Ribeiro MA Jr, Rizoli S, Fraga GP, Rezende-Neto JB. Is there a role for pyloric exclusion after severe duodenal trauma? *Rev Col Bras Cir*. 2014;41(3):228–231.
  22. Stone HH, Garoni WJ. Experiences in the management of duodenal wounds. *South Med J*. 1966;59:864.
  23. Stone HH, Fabian TC. Management of duodenal wounds. *J Trauma*. 1979;19(5):334–339.
  24. Dubose JJ, Inaba K, Teixeira PG, Shiflett A, Putty B, Green DJ, Plurad D, Demetriades D. Pyloric exclusion in the treatment of severe duodenal injuries: results for the National Trauma Data Bank. *Am Surg*. 2008;74(10):925–929.
  25. Ivatury RR, Gaudino J, Ascer E, Nallathambi M, Ramirez-Schon G, Stahl WM. Treatment of penetrating duodenal injuries: primary repair vs. repair with decompressive enterostomy/serosal patch. *J Trauma*. 1985;25(4):337–341.
  26. Seamon MJ, Pieri PG, Fisher CA, Gaughan J, Santora TA, Pathak AS, Bradley KM, Goldberg AJ. A ten-year retrospective review: does pyloric exclusion improve clinical outcome after penetrating duodenal and combined pancreaticoduodenal injuries? *J Trauma*. 2007;62(4):829–833.
  27. Nassoura ZE, Ivatury RR, Simon RJ, Stahl WM. A prospective reappraisal of primary repair of penetrating duodenal injuries. *Am Surg*. 1994;60(1):35–39.
  28. Moore FA, Feliciano DV, Andrassy RJ, McArdle AH, Booth FV, Morgenstein-Wagner TB, Kellum JM Jr, Welling RE, Moore EE. Early enteral feeding, compared with parenteral, reduces postoperative septic complications. The results of a meta-analysis. *Ann Surg*. 1992;216(2):172–183.