

# Evaluation and management of bowel and mesenteric injuries after blunt trauma: A Western Trauma Association critical decisions algorithm

Jordan A. Weinberg, MD, Kimberly A. Peck, MD, Eric J. Ley, MD, Carlos V. Brown, MD, Ernest E. Moore, MD, Jason L. Sperry, MPH, MD, Anne G. Rizzo, MD, Nelson G. Rosen, MD, Karen J. Brasel, MPH, MD, Jennifer L. Hartwell, MD, Marc A. de Moya, MD, Kenji Inaba, MD, and Matthew J. Martin, MD, Phoenix, Arizona

## CONTINUING MEDICAL EDUCATION CREDIT INFORMATION

### Accreditation

This activity has been planned and implemented in accordance with the Essential Areas and Policies of the Accreditation Council for Continuing Medical Education (ACCME) through the joint providership of the American College of Surgeons and American Association for the Surgery of Trauma. The American College of Surgeons is accredited by the ACCME to provide continuing medical education for physicians.

### AMA PRA Category 1 Credits™

The American College of Surgeons designates this journal-based activity for a maximum of 1.00 AMA PRA Category 1 Credit™. Physicians should claim only the credit commensurate with the extent of their participation in the activity. Of the AMA PRA Category 1 Credit™ listed above, a maximum of 1.00 credit meets the requirements for self-assessment.



AMERICAN COLLEGE OF SURGEONS  
Inspiring Quality:  
Highest Standards, Better Outcomes



AMERICAN COLLEGE OF SURGEONS  
DIVISION OF EDUCATION

### Objectives

After reading the featured articles published in the *Journal of Trauma and Acute Care Surgery*, participants should be able to demonstrate increased understanding of the material specific to the article. Objectives for each article are featured at the beginning of each article and online. Test questions are at the end of the article, with a critique and specific location in the article referencing the question topic.

### Disclosure Information

In accordance with the ACCME Accreditation Criteria, the American College of Surgeons must ensure that anyone in a position to control the content of the educational activity (planners and speakers/authors/discussants/moderators) has disclosed all financial relationships with any commercial interest (termed by the ACCME as “ineligible companies”, defined below) held in the last 24 months (see below for definitions). Please note that first authors were required to collect and submit disclosure information on behalf all other authors/contributors, if applicable.

**Ineligible Company:** The ACCME defines a “commercial interest” as any entity producing, marketing, re-selling, or distributing health care goods or services used on or consumed by patients. Providers of clinical services directly to patients are NOT included in this definition.

**Financial Relationships:** Relationships in which the individual benefits by receiving a salary, royalty, intellectual property rights, consulting fee, honoraria, ownership interest (e.g., stocks, stock options or other ownership interest, excluding diversified mutual funds), or other financial benefit. Financial benefits are usually associated with roles such as employment, management position, independent contractor (including contracted research), consulting, speaking and teaching, membership on advisory committees or review panels, board membership, and other activities from which remuneration is received, or expected. ACCME considers relationships of the person involved in the CME activity to include financial relationships of a spouse or partner.

**Conflict of Interest:** Circumstances create a conflict of interest when an individual has an opportunity to affect CME content about products or services of a commercial interest with which he/she has a financial relationship.

The ACCME also requires that ACS manage any reported conflict and eliminate the potential for bias during the session. Any conflicts noted below have been managed to our satisfaction. The disclosure information is intended to identify any commercial relationships and allow learners to form their own judgments. However, if you perceive a bias during the educational activity, please report it on the evaluation.

AUTHORS/CONTRIBUTORS				
<i>Ernest E. Moore, Haemonetics/Instrumentation Laboratory/Stago/ThromboTherapeutics; Grant/Grant/Grant/Royalties; PI/PI/PI/Co-Founder. Jordan A. Weinberg, Kimberly A. Peck, Eric J. Ley, Carlos V. Brown, Jason L. Sperry, Anne G. Rizzo, Nelson G. Rosen, Karen J. Brasel, Jennifer L. Hartwell, Marc A. deMoya, Kenji Inaba, Matthew J. Martin - No Disclosures.</i>				
PLANNING COMMITTEE / EDITORIAL COMMITTEE	NOTHING TO DISCLOSE	DISCLOSURE		
		COMPANY	ROLE	RECEIVED
<i>Ernest E. Moore, Editor</i>		<i>Haemonetics</i>	<i>PI</i>	<i>Shared U.S. Patents</i>
		<i>Instrumentation Laboratory</i>	<i>PI</i>	<i>Research Support</i>
		<i>Stago, Humacyte, Pxytime, Genentech</i>	<i>PI</i>	<i>Research Support</i>
		<i>ThromboTherapeutics</i>	<i>Co-founder</i>	<i>Stock</i>
<i>Associate Editors David B. Hoyt, Ronald V. Maier, and Steven Shackford</i>	<i>X</i>			
<i>Editorial Staff and Angela Sautia</i>	<i>X</i>			

### Claiming Credit

To claim credit, please visit the AAST website at <http://www.aast.org/> and click on the “e-Learning/MOC” tab. You must read the article, successfully complete the post-test and evaluation. Your CME certificate will be available immediately upon receiving a passing score of 75% or higher on the post-test. Post-tests receiving a score of below 75% will require a retake of the test to receive credit.

### Credits can only be claimed online

#### Cost

For AAST members and *Journal of Trauma and Acute Care Surgery* subscribers there is no charge to participate in this activity. For those who are not a member or subscriber, the cost for each credit is \$25.

#### Questions

If you have any questions, please contact AAST at 800-789-4006. Paper test and evaluations will not be accepted.

**KEY WORDS:** Blunt trauma; bowel injury; mesenteric injury; practice guidelines.

This is a recommended evaluation and management algorithm from the Western Trauma Association (WTA) Algorithms Committee addressing the management of adult patients with potential bowel and/or mesenteric injuries resulting from blunt trauma. Because there is a paucity of published prospective randomized clinical trials that have generated class I data, these recommendations are based primarily on published prospective and retrospective cohort studies, and expert opinion of the WTA members. The final algorithm is the result of an iterative process including an initial internal review and revision by the WTA Algorithm Committee members, followed by final revisions based on input during and after presentation of the algorithm to the full WTA membership.

Significant blunt bowel and/or mesenteric injury (BBMI), that is, that requiring operative intervention, presents a diagnostic challenge because it occurs infrequently and can develop insidiously. Although computed tomography (CT) cross-sectional imaging of the abdomen and pelvis is widely applied following blunt trauma, findings can be nonspecific. The surgeon is faced with determining whether the patient has significant BBMI, requiring operative management, versus an insignificant injury that will resolve without treatment. Unrecognized significant BBMI is the most frequent cause for delayed intervention after blunt abdominal trauma, and a diagnostic delay of 5 to 8 hours has a negative impact on survival.<sup>1,2</sup> Nonetheless, 45% to 70% of patients with evidence for BBMI on initial CT imaging will not require surgical repair, and nontherapeutic laparotomy exposes patients to risk for both early and late complications including atelectasis, wound complications, adhesive bowel obstruction, and incisional hernia.<sup>3–5</sup> Surgical decision making for such patients is predicated on the synthesis of imaging findings and clinical variables with respect to choosing operative management versus serial clinical evaluation. The intent of this WTA Critical Decisions Algorithm is to provide a structured pathway for this decision.

The algorithm (Fig. 1) and accompanying comments represent a safe and sensible approach to the evaluation of the

patient with suspected BBMI. We recognize that there will be multiple factors that may warrant or require deviation from any single recommended algorithm and that no algorithm can completely replace expert bedside clinical judgment. We encourage clinicians to use this as a general framework in the approach to these patients and to customize and adapt the algorithm to better suit the specifics of their program or location.

## ALGORITHM

The following lettered sections correspond to the letters identifying specific sections of the algorithm shown in Figure 1. In each section, we have provided a brief summary of the important aspects and options that should be considered at that point in the evaluation and management process.

### A. Identification of Patients at Risk for BBMI From Mechanism of Injury

There are three primary mechanisms of injury that may result in BBMI.<sup>6</sup> A direct blow to the abdomen may cause BBMI as a result of compression. Rapid deceleration as a result of shearing forces from high-velocity impact may cause tears in the bowel mesentery resulting in devascularization injuries. Lastly, sudden increases in intra-abdominal pressure (Valsalva-type effect) may cause perforation of a hollow viscus. Therefore, patients injured as a result of the above mechanisms should be considered for the possibility of having BBMI. Typical scenarios would include direct blows to the abdomen (physical assault, seatbelt compression), high-speed vehicular collisions, fall from significant height, pedestrian or cyclist struck by vehicle at high speed, and impact of restraints causing sudden increase in intra-abdominal pressure.

### B. Identification of Patients Requiring Immediate Operative Intervention

On presentation to the emergency department, the hemodynamically unstable patient must be rapidly assessed for intra-abdominal hemorrhage as a potential cause of shock. Intra-abdominal fluid identified on focused assessment with sonography for trauma examination in an unstable patient is an indication for immediate laparotomy, as it strongly suggests the presence of intra-abdominal hemorrhage. In the event of a negative focused assessment with sonography for trauma with ongoing suspicion for intra-abdominal hemorrhage (or lack of availability of ultrasound), diagnostic peritoneal aspiration may be performed. In the unstable patient, the finding of 10 mL of blood in the peritoneal cavity on diagnostic peritoneal aspiration would also be an indication for immediate laparotomy.

Plain x-rays of the chest and pelvis are often obtained as an adjunct to the primary survey in the evaluation of blunt trauma patients. The presence of free intra-abdominal air on plain x-rays is an indication to proceed with laparotomy, with the caveat that a large pneumothorax may result in air dissection below the diaphragm resulting in pneumoperitoneum. Peritoneal signs on physical examination may also be indicative of bowel injury. In practice, however, it is often difficult to distinguish

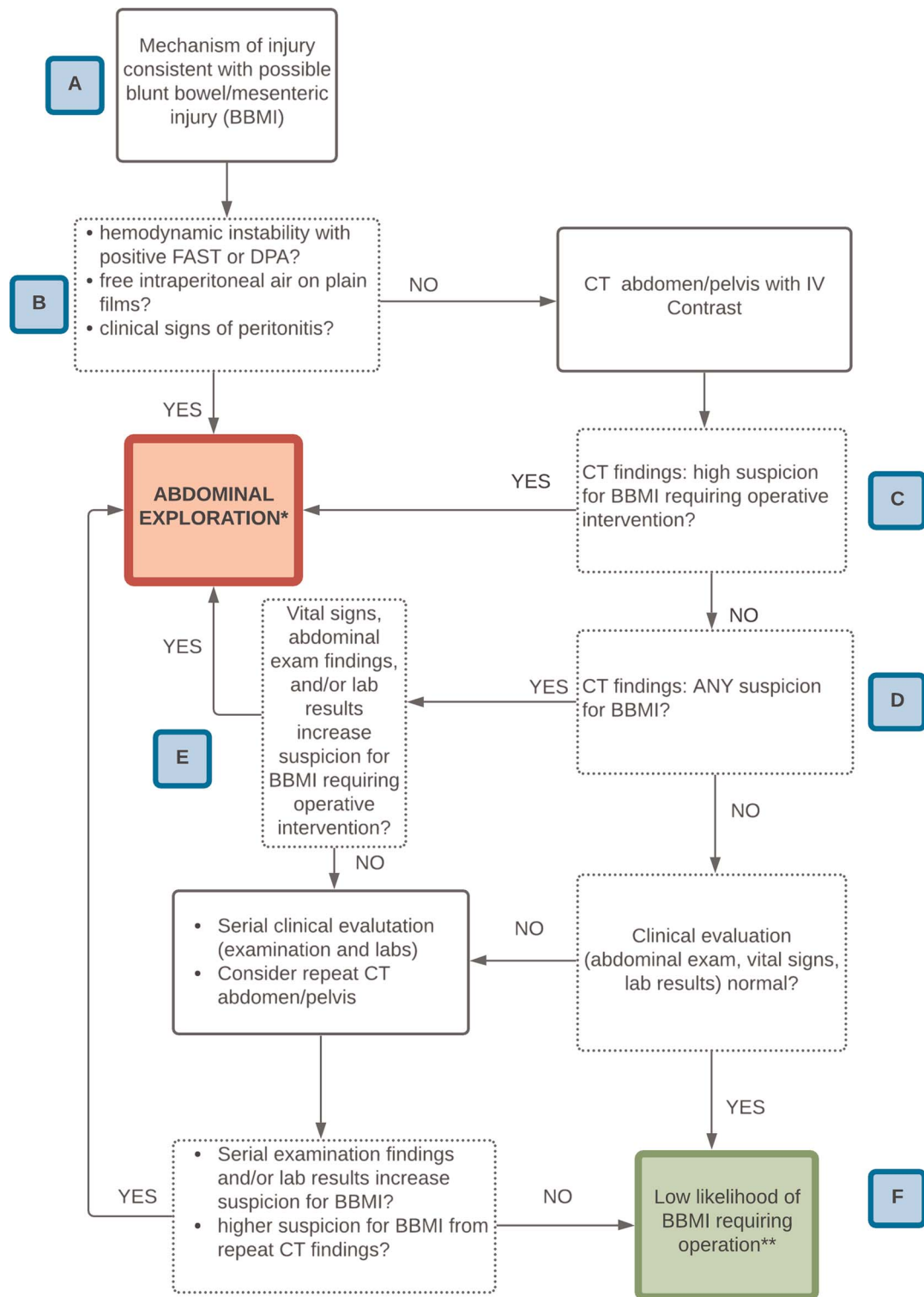
Submitted: April 21, 2021, Revised: May 21, 2021, Accepted: May 27, 2021, Published online: June 22, 2021.

From the Department of Surgery, Creighton University School of Medicine Phoenix Regional Campus (J.A.W.), Phoenix, Arizona; Department of Surgery, Scripps Mercy Hospital (K.A.P., M.J.M.), San Diego; Department of Surgery, Cedars-Sinai Medical Center (E.J.L.), Los Angeles, California; Department of Surgery, Dell Medical School, University of Texas (C.V.B.), Austin, Texas; Department of Surgery, Ernest E. Moore Shock Trauma Center (E.E.M.), Denver, Colorado; Department of Surgery, University of Pittsburgh School of Medicine, (J.L.S.), Pittsburgh, Pennsylvania; Department of Surgery, Inova Trauma Center (A.G.R.), Falls Church, Virginia; Department of Surgery, Cincinnati Children's Hospital (N.G.R.), Cincinnati, Ohio; Department of Surgery, Oregon Health Science University (K.J.B.), Portland, Oregon; Department of Surgery, Indiana University School of Medicine (J.L.H.), Indianapolis, Indiana; Department of Surgery, Medical College of Wisconsin (M.A.d.M.), Milwaukee, Wisconsin; Department of Surgery, University of Southern California (K.I.), Los Angeles, California.

This study was presented at the 51st Annual Western Trauma Association Meeting, March 3, 2021, virtual session.

Address for reprints: Jordan A. Weinberg, MD, Department of Surgery, Creighton University School of Medicine Phoenix Regional Campus, Trauma Administration, St. Joseph's Hospital and Medical Center, 350 W. Thomas Rd, Phoenix, AZ; email: jordanweinberg@creighton.edu.

DOI: 10.1097/TA.0000000000003327



**Figure 1.** Western Trauma Association algorithm for the evaluation and management of patients for BBMI requiring operative intervention. Boxed letters correspond to sections in the associated manuscript. \*The criterion standard for abdominal exploration is via laparotomy. However, diagnostic and/or therapeutic laparoscopy may be performed in select stable patients and by an appropriately skilled surgeon experienced in minimally invasive surgical techniques. \*\*Patient may be discharged if no other indication for continued hospitalization.

peritoneal signs from generalized tenderness in trauma patients, especially if mental status is impaired.

### C. CT Findings Suggestive of High Risk for Significant BBMI

In patients without an indication for immediate operative intervention as outlined in Section B, CT imaging of the abdomen and pelvis should be performed. Intravenous contrast is strongly recommended. Oral contrast is unnecessary for the initial CT scan because it is not particularly helpful in injury detection and can also contribute to significant delay in obtaining imaging and making a diagnosis.<sup>7</sup> Operative intervention is indicated if there are CT findings highly suggestive of BBMI. There are three pathognomonic CT findings or “hard signs” for BBMI: bowel wall discontinuity (which may be seen with or without oral contrast), extraluminal air (with the exception of pneumoperitoneum as a result of pneumothorax as described in Section B<sup>8</sup>), and vascular blush or extravasation in the mesentery. These three findings warrant operative management. Other findings on CT may be associated with BBMI but are not themselves indicative of a need for operative intervention. These “soft signs” include free fluid (particularly in the absence of solid organ injury), focal bowel wall thickening, nonenhancing bowel, and mesenteric stranding. The presence of multiple soft signs should signal to the surgeon that significant BBMI is likely and operative intervention is warranted.

The imaging finding of free fluid deserves further discussion. When associated with solid organ injury and of high density, it may be simply representative of blood from the injured solid organ. In the absence of solid organ injury, free fluid is more worrisome but may nonetheless be relatively benign: physiologic in women or a result of self-limited bleeding from an inconsequential rent in the retroperitoneum or mesentery that has collected in the peritoneal cavity.<sup>9</sup> In female patients, free pelvic fluid isolated to the pouch of Douglas that is low in density and does not extend more superiorly than the S3 body may be considered “physiologic.”<sup>10</sup> Nonetheless, any amount of free fluid associated with any of the other soft signs as described previously suggests significant BBMI, and operative intervention is warranted. A moderate to large volume of free fluid with no other soft signs present (either in the absence of solid organ injury or relative to what would be expected from solid organ injury in a stable patient) is highly suspicious for BBMI and also warrants operative intervention. In addition to bowel injury, the fluid may be indicative of intraperitoneal bladder rupture. A caveat to this directive would be suspicion that the free fluid is not blood, urine, and/or succus but rather ascites related to underlying cirrhosis (a known history of cirrhosis, morphologic characteristics of a cirrhotic liver on CT, and/or low-density simple fluid would support this suspicion and could be confirmed by needle aspiration of the free fluid). Nonetheless, erring toward the side of operative versus intervention versus observation is recommended, given the known mortality risk associated with delay.

### D. CT Findings Suggestive of Possible Significant BBMI

Less substantial findings on CT that are not considered highly suspicious for significant BBMI but warrant consideration

of underlying BBMI that will require operative intervention may be observed. Such findings would include isolated soft signs, such as mesenteric stranding or small volume free fluid, often described in radiology reports as “trace.” Other findings that warrant suspicion for BBMI include traumatic abdominal wall hernia and seatbelt-related stranding and/or hematoma of the abdominal wall. For patients with any of these findings on CT imaging, BBMI cannot be ruled out, and consideration of the patient’s clinical picture in context with the CT findings is warranted.

### E. Operative Intervention Versus Serial Clinical Evaluation

Should the CT scan reveal any suspicion for BBMI, clinical judgment is necessary with respect to choosing operative intervention versus serial clinical examination with or without repeat imaging. Systemic/constitutional findings such as tachycardia or fever increase the likelihood of significant BBMI, as does abdominal ecchymosis (i.e., the “seat belt sign”), and tenderness and/or distention in the setting of an abnormal CT scan. Leukocytosis and/or acidosis can also suggest significant BBMI. Although abdominal exploration may result in a nontherapeutic procedure, as stated previously, we recommend a low threshold for operative exploration rather than observation. Diagnostic laparoscopy may be used selectively by surgeons with appropriate skills; however, laparotomy remains the criterion standard for operative exploration for BBMI. During laparoscopy, adequate visualization of the entire bowel and mesentery may be compromised by intraperitoneal blood, which should prompt conversion to laparotomy.

Patients with an abnormal CT without any clinical evidence for BBMI (i.e., normal vitals, laboratory results, and abdominal examination) may undergo close observation with the understanding that relatively short delays to intervention (as early as 5–8 to 24 hours) contribute to increased risk for morbidity and mortality.<sup>1,2,11</sup> Close clinical monitoring and with serial abdominal examinations and repeat laboratory parameters is warranted. Should the patient’s clinical picture worsen as manifest by worsening abdominal pain and/or development of concerning laboratory findings, operative exploration is warranted. A patient with a stable to improved clinical assessment is unlikely to have significant BBMI.

The duration of observation necessary to exclude significant BBMI remains unclear; at least 24 hours is recommended. Repeat CT scan approximately 24 hours following admission may be used to evaluate for changes in appearance of fluid and/or stranding or for new findings such as extraluminal air. This may be particularly useful for patients with an unreliable physical examination secondary to associated brain injury or other neurologic compromise.

Diagnostic peritoneal lavage is seldom used in contemporary practice. It may be entertained for the rare patient with poorly controlled intracranial hypertension at risk for exacerbation with transport and supine positioning for a CT scan. Lavage fluid that appears grossly bilious (or otherwise suspicious for succus) or has measurable levels of amylase or alkaline phosphatase is consistent with hollow viscus injury.

## F. Determining Low Likelihood of BBMI Requiring Operative Intervention

Although patients with no abnormal findings on initial CT are unlikely to have underlying BBMI requiring operative intervention, a normal CT scan does not completely rule out BBMI.<sup>12,13</sup> A patient may have a significant mesenteric tear that is not evident on initial imaging but results in insidious bowel ischemia and late presentation of segmental bowel necrosis, which can occur 3 to 7 days following injury. Nonetheless, because this is a rare scenario, discharge home is reasonable for those patients meeting discharge criteria. Such patients should be counseled to return to the hospital immediately should they develop worsening abdominal pain, nausea, or fever. For patients remaining in hospital for management of extra-abdominal injuries, monitoring specifically for BBMI may be discontinued, but any onset of symptoms or signs consistent with BBMI later in the hospital course should be immediately evaluated with repeat CT imaging.

Patients with an abnormal initial CT who are observed for at least 24 hours without clinical worsening, especially with a repeat CT that demonstrates stability or improvement of the initial CT findings, are also unlikely to have underlying significant BBMI. The decision to continue surveillance beyond this time must be individualized according to the patient's CT findings (minimal vs. more extensive), examination reliability (awake, tolerating diet vs. obtunded from extra-abdominal injuries, substance abuse, etc.), and overall injury burden.

## AREAS OF CONTROVERSY AND EXISTING KNOWLEDGE/RESEARCH GAPS

It is also important to note that there are many areas of this algorithm that lack high-quality evidentiary support and where further focused research is required:

1. Role of repeat CT imaging. Single-institution studies suggest that repeat CT scan improves positive and negative predictive value for BBMI compared with the initial CT alone.<sup>14,15</sup> The optimal timing of repeat imaging is unclear; the need for some duration of time to pass to allow for observable change from the first CT must be balanced against incurring delayed operative intervention. Common practice is to obtain the repeat CT approximately 24 hours following admission. Addition of oral contrast has not been shown to necessarily improve diagnostic performance but is a reasonable adjunct for repeat CT, as it would not inherently result in any delay. Repeat CT is a potentially useful test to help guide decision making, particularly for patients who do not have a reliable physical examination. Excess radiation exposure is another consideration that is particularly relevant to the younger patient. It is recommended that dose reduction strategies for cross-sectional imaging be used according to local practices.
2. Duration of observation. Serial clinical evaluation for the development of constitutional or focal abdominal signs of BBMI warranting operative intervention is often performed, but the optimally safe duration of observation has yet to be established. Although the majority of patients observed for BBMI undergo operation within 24 hours, there are still instances whereby operative intervention is delayed for days,

likely as a result of devascularized bowel becoming clinically evident only after the onset of bowel necrosis. No study has yet to evaluate the optimal duration of observation. Given that existing retrospective studies demonstrate that significant BBMI generally manifests within 24 hours, we recommend that clinical serial examinations be performed at a minimum for this interval of time.

3. Surgical decision-making tools. A number of scoring tools have been described (based on CT findings or a combination of imaging and clinical findings) with sensitivity and specificity, and positive and negative predictive values that are reasonably high.<sup>16-20</sup> However, few have been externally validated. McNutt et al.<sup>16</sup> described the Bowel Injury Prediction Score based on admission CT findings, white blood cell count, and abdominal tenderness (present or absent). Although the authors reported a positive predictive value of 70.6%, retrospective evaluation of Bowel Injury Prediction Score by Zingg et al.<sup>21</sup> at their own institution resulted in a positive predictive values of only 19.0%. Similarly, Faget et al.<sup>18</sup> described a scoring system based on initial CT findings with negative predictive value of 99.6%, but external evaluation by Lannes et al.<sup>15</sup> demonstrated a negative predictive value of only 77.4%. The described scores have yet to be widely adopted. We recommend that adoption of any scoring system for clinical decision making be deferred until prospective external validation of the scoring system is successfully completed.

## AUTHORSHIP

J.A.W. and M.J.M. contributed in the conception and design. J.A.W. contributed in the drafting of the article. K.A.P., E.J.L., C.V.B., E.E.M., J.L.S., A.G.R., N.G.R., K.J.B., J.L.H., M.A.M., K.I., and M.J.M. contributed in the Critical revision of the article.

All authors meet authorship criteria for this article. All authors have seen and approved the final article as submitted. The first author (J.A.W.) had full access to all data in the study and takes responsibility for the integrity of the data and the accuracy of the data analysis.

## DISCLOSURE

The authors declare no conflicts of interest.

The results and opinions expressed in this article are those of the authors and do not reflect the opinions or official policy of any of the listed affiliated institutions, the United States Army, or the Department of Defense (if military coauthors).

## REFERENCES

1. Fakhry SM, Brownstein M, Watts DD, Baker CC, Oller D. Relatively short diagnostic delays (<8 hours) produce morbidity and mortality in blunt small bowel injury: an analysis of time to operative intervention in 198 patients from a multicenter experience. *J Trauma*. 2000;48(3):408-414.
2. Malinoski DJ, Patel MS, Yakar DO, Green D, Qureshi F, Inaba K, Brown CV, Salim A. A diagnostic delay of 5 hours increases the risk of death after blunt hollow viscus injury. *J Trauma*. 2010;69(1):84-87.
3. Haan J, Kole K, Brunetti A, Kramer M, Scalea TM. Nontherapeutic laparotomies revisited. *Am Surg*. 2003;69(7):562-565.
4. Morrison J, Wisner D, Bodai B. Complications after negative laparotomy for trauma: long-term follow-up in a health maintenance organization. *J Trauma*. 1996;41:509-513.
5. Renz B, Feliciano D. Unnecessary laparotomies for trauma: a prospective study of morbidity. *J Trauma*. 1995;30:350-356.
6. Cinquantini F, Tugnoli G, Piccinini A, Coniglio C, Mannone S, Biscardi A, Gordini G, Di Saverio S. Educational review of predictive value and findings of computed tomography scan in diagnosing bowel and mesenteric injuries

- after blunt trauma: correlation with trauma surgery findings in 163 patients. *Can Assoc Radiol J*. 2017;68(3):276–285.
7. Clancy TV, Ragozzino MW, Ramshaw D, Churchill MP, Covington DL, Maxwell JG. Oral contrast is not necessary in the evaluation of blunt abdominal trauma by computed tomography. *Am J Surg*. 1993;166(6):680–684.
  8. Marek AP, Deisler RF, Sutherland JB, Punjabi G, Portillo A, Krook J, Richardson CJ, Nygaard RM, Ney AL. CT scan-detected pneumoperitoneum: an unreliable predictor of intra-abdominal injury in blunt trauma. *Injury*. 2014;45(1):116–121.
  9. Gonser-Hafertepen LN, Davis JW, Bilello JF, Ballow SL, Sue LP, Cagle KM, Venugopal C, Hafertepen SC, Kaups KL. Isolated free fluid on abdominal computed tomography in blunt trauma: watch and wait or operate? *J Am Coll Surg*. 2014;219(4):599–605.
  10. Gunn ML, ed. *Pearls and Pitfalls in Emergency Radiology: Variants and Other Difficult Diagnoses*. 1st ed. New York, NY: Cambridge University Press; 2013.
  11. Watts DD, Fakhry SM, EAST Multi-Institutional Hollow Viscus Injury Research Group. Incidence of hollow viscus injury in blunt trauma: an analysis from 275,557 trauma admissions from the East multi-institutional trial. *J Trauma*. 2003;54(2):289–294.
  12. Livingston DH, Lavery RF, Passannante MR, Skurnick JH, Fabian TC, Fry DE, Malangoni MA. Admission or observation is not necessary after a negative abdominal computed tomographic scan in patients with suspected blunt abdominal trauma: results of a prospective, multi-institutional trial. *J Trauma*. 1998;44(2):273–280.
  13. Fakhry SM, Allawi A, Ferguson PL, Michetti CP, Newcomb AB, Liu C, Brownstein MR, EAST small bowel perforation (SBP) Multi-Center Study Group. Blunt small bowel perforation (SBP): an Eastern Association for the Surgery of Trauma multicenter update 15 years later. *J Trauma Acute Care Surg*. 2019;86(4):642–650.
  14. Walker ML, Akpele I, Spence SD, Henderson V. The role of repeat computed tomography scan in the evaluation of blunt bowel injury. *Am Surg*. 2012;78(9):979–985.
  15. Lannes F, Scemama U, Maignan A, Boyer L, Beyer-Berjot L, Berdah SV, Chaumoitre K, Leone M, Bège T. Value of early repeated abdominal CT in selective non-operative management for blunt bowel and mesenteric injury. *Eur Radiol*. 2019;29(11):5932–5940.
  16. McNutt MK, Chinapuvvula NR, Beckmann NM, Camp EA, Pommerening MJ, Laney RW, West OC, Gill BS, Kozar RA, Cotton BA, et al. Early surgical intervention for blunt bowel injury: the Bowel Injury Prediction Score (BIPS). *J Trauma Acute Care Surg*. 2015;78(1):105–111.
  17. Raharimanantsoa M, Zingg T, Thiery A, Brigand C, Delhomme JB, Romain B. Proposal of a new preliminary scoring tool for early identification of significant blunt bowel and mesenteric injuries in patients at risk after road traffic crashes. *Eur J Trauma Emerg Surg*. 2018;44(5):779–785.
  18. Faget C, Taourel P, Charbit J, Ruyer A, Alili C, Molinari N, Millet I. Value of CT to predict surgically important bowel and/or mesenteric injury in blunt trauma: performance of a preliminary scoring system. *Eur Radiol*. 2015;25(12):3620–3628.
  19. Filiberto DM, Afzal MO, Sharpe JP, Seger C, Shankar S, Croce MA, Fabian TC, Magnotti LJ. Radiographic predictors of therapeutic operative intervention after blunt abdominal trauma: the RAPTOR score. *Eur J Trauma Emerg Surg*. 2020; Epub ahead of print.
  20. Zarour A, El-Menyar A, Khattabi M, Tayyem R, Hamed O, Mahmood I, Abdelrahman H, Chiu W, Al-Thani H. A novel practical scoring for early diagnosis of traumatic bowel injury without obvious solid organ injury in hemodynamically stable patients. *Int J Surg*. 2014;12(4):340–345.
  21. Zingg T, Agri F, Bourgeat M, Yersin B, Romain B, Schmidt S, Keller N, Demartines N. Avoiding delayed diagnosis of significant blunt bowel and mesenteric injuries: Can a scoring tool make the difference? A 7-year retrospective cohort study. *Injury*. 2018;49(1):33–41.